

# 8

## Nonsurgical Rejuvenation of the Face using Botulinum Toxin and Fillers

*Kuldeep Singh and Chiranjiv Chhabra*

➤ **Introduction**

➤ **Botulinum Toxin**

• **Upper Face**

- ◇ Glabellar Lines and Eyebrows
- ◇ Browlift and Reshaping
- ◇ Forehead Lines
- ◇ Periorbital Area
- ◇ Adverse Effects

• **Midface**

- ◇ Scrunch Lines
- ◇ Nasal Tip Ptosis
- ◇ Gummy Smile
- ◇ Adverse Effects

• **Lower Face**

- ◇ Perioral Lines
- ◇ Marionette Lines
- ◇ Puckered or “Popply” Chin
- ◇ Adverse Effects

➤ **Injectable Fillers**

• **Upper Third of Face**

- ◇ Forehead and Suprabrow
- ◇ Periorbital (Periocular) Area

• **Midface**

- ◇ Tear Trough
- ◇ Lateral SOOF
- ◇ Nasolabial Fold
- ◇ Nose

• **Lower Face**

- ◇ Perioral Rejuvenation
- ◇ Marionette Folds/Lines
- ◇ Chin
- ◇ Jawline

• **Adverse Effects of Fillers**

- ◇ Pain
- ◇ Edema and Bruising
- ◇ Erythema
- ◇ Infections
- ◇ Nodules and Lumps
- ◇ Tyndall Effect
- ◇ Hypersensitivity Reactions
- ◇ Malar Edema
- ◇ Vascular Compromise

➤ **Full-Face Rejuvenation**

• **Assessment**

• **Planning and Execution**

➤ **Conclusion**

## Introduction

Aging is a natural physiological phenomenon characterized by both intrinsic and extrinsic changes in the body. Age-related skin changes are visible and come into focus early. The pain of visible aging leads a person to seek a solution to his/her aesthetic problem. Many of the age-related changes are inevitable but can be slowed down by adopting wiser lifestyles, an appropriate skin care routine, and timely medical intervention in the form of procedures like dermal filler injections, neurotoxins, energy-based devices, chemical peels, regenerative medical solutions, and many more options. The Gold standard for antiaging is a combination approach.

In this chapter we will be concentrating on the use of hyaluronic acid (HA) fillers and neurotoxins to address aging issues. We are well aware that aging can be categorized into photoaging and chronological aging. Facial aging is a sum total of changes occurring in four layers: skin, fat, muscle, and bone. Bone—resorption; soft tissue—atrophy; fat—resorption and migration; skin atrophy. Four Rs of facial rejuvenation were earlier described by Woffles Wu,<sup>1</sup> but in today's context there are actually 6 Rs which are needed. Therefore as clinicians we should adopt the 6R technique of what can be called the comprehensive age management (CAM) plan (**Box 8.1**).

The concept of aging and beauty has been evolving rapidly over the past decade. In our practice of injectables spread over 20 years, we have observed the following:

- Patients are seeking aesthetic intervention at an earlier age. In a study of patients coming for facelifts, 32% reported having received injectables for facial rejuvenation starting at an average age of 37 years.<sup>2,3</sup> Now, even in India the patients are coming in their 30s for antiaging, as well as seeking enhancement of facial features as early as the 20s.<sup>4</sup>
- Earlier mostly women were seeking aesthetic improvement, now men are also seeking solutions in ever increasing numbers, though women still form the majority of patients in an aesthetic clinic.
- Earlier the focus was on looking younger. Now the focus is on (enhancement) beautification as well as looking more youthful.

### Box 8.1 Comprehensive age management (CAM) plan

- R1** Relax—The hyperdynamic muscles of the face
- R2** Restore—The depleted soft tissue volume
- R3** Rejuvenate—Improve skin laxity
- R4** Resurface—Improve skin quality, texture, and pigmentation
- R5** Reshape—Give support to the bony profile of the face and enhance landmarks
- R6** Rehabilitate—Constant upkeep by follow-ups and touch-ups

The mindset of the treating physician is also changing from antiaging alone toward enhancement along with antiaging, contributing to better outcomes.

## Botulinum Toxin

BontA is one of the serotypes produced from fermentation of clostridium botulinum in an anaerobic environment. In a nutshell, intramuscular injection of BontA inhibits the release of acetylcholine from motor nerve terminals, from autonomous nerve terminals, as well as secretomotor terminals having acetylcholine as neurotransmitter.

Botulinum toxin A (specifically OnabotulinumA) has been approved for more than 25 indications worldwide for indications involving bigger muscles including cervical dystonia, lower and upper limb spasticity, and for smaller muscles like glabellar frown lines, strabismus and blepharospasm. It is also approved for use in migraine, axillary hyperhidrosis and neurogenic overactive bladder.

In 2002, FDA approved Botox for treating frown lines, crow's feet, and forehead lines for aesthetic improvement. Double-blind, placebo-controlled trials by Carruthers et al<sup>5</sup> have established safety and efficacy of the toxin, supported also by many studies across Asia. The response rate was uniformly >80%, with a median duration of 120 days. Its onset of action appears in 3 days in most of the patients, with almost half of them reporting the effect in 24 hours.<sup>6</sup> Adverse effects were reported in a large series of 537 patients (treating glabellar lines and crow's feet), where authors<sup>7</sup> observed that overall incidence was not different in BontA versus placebo. Eyelid ptosis (3.2%) occurred in a significantly higher number in the BontA than in the placebo group, and interestingly, occurred only when the glabellar lines were injected. As the number of treatment cycles increased, the incidence of this adverse effect decreased to 0.8%.

From among various serotypes, viz., A, B, C1, D, E, F, and G, serotype A (Onabotulinum A—Botox, Incobotulinum A—Xeomin, Abobotulinum A—Dysport) is commonly used.

The only serotype B used is Rimabotulinum B toxin (Myobloc). The new kid on the block is Jeuveau (Prabotulinum toxin A),<sup>8</sup> which has already undergone Phase III studies for safety and efficacy in the treatment of glabellar lines. There are other newer toxins which are undergoing Phase IIa trials, like the RT002, also known as Daxibotulinum toxin A.<sup>9</sup>

Most of the BontA preparations are complex, with a protective protein shell called NAP (neurotoxin-associated protein), except Xeomin where all the proteins have been removed during the purification process. Onabotulinum A (Botox) preparation comes as a vacuum dried powder, while the rest come as lyophilized powders. Rimabotulinum B comes as a reconstituted solution.

Unpreserved saline was used to reconstitute Onabotulinum A earlier, but use of even preserved saline shows no decrease in efficacy, and is also less painful.

Sterile water does not decrease efficacy, but the injection is extremely painful. Agitation/foaming of the solution is known to produce no reduction in efficacy. Storage after reconstitution in normal saline has been found to have no reduction in efficacy for 2 to 6 weeks in various studies.<sup>10,11</sup>

Dilution has also been a subject of controversy, with current recommendations for Onabotulinum A ranging from 1 to 3 mL, 2.5 mL being the current standard recommended dilution. It was observed in a study by Hsu et al in 2004<sup>12</sup> that BontA showed greater diffusion with greater dilution, and Carruthers et al in 2007<sup>13</sup> showed more ptosis in the higher dilution group while treating the glabella, although the difference was not statistically significant. We personally prefer a dilution of 2 mL for a vial of 100 U (50 U/mL) for most indications.

## Upper Face

### Glabellar Lines and Eyebrows

Onabotulinum A was approved by the FDA for use in glabellar lines only in 2002, although it has been used for the same indication for over two decades as an off-label indication.

It is the first effective and noninvasive technique for browlift and improvement in glabellar lines described by Carruthers et al in 2003.<sup>14</sup> They showed that both dynamic and resting glabellar lines improved with botulinum toxin. Subsequently, it was also used for treating forehead lines, lines in the periocular area and other lines.

It has been seen that injection of Onabotulinum A into the procerus and corrugator supercilii not only relaxes the glabella, but also the medial frontalis due to deeper diffusion. This also causes lowering of the medial end of the eyebrows and elevation of the middle and lateral brow, mostly to our advantage in improving the shape of the eyebrows. Twenty to twenty-four units when injected in women, and 20 to 40 units in men will give an adequate response in the glabellar region (**Fig. 8.1**). Indian consensus guidelines suggest 16 to 20 units over three to five points<sup>7</sup> with the lateral points staying medial to the midpupillary line, at least 1 cm above the eyebrow.

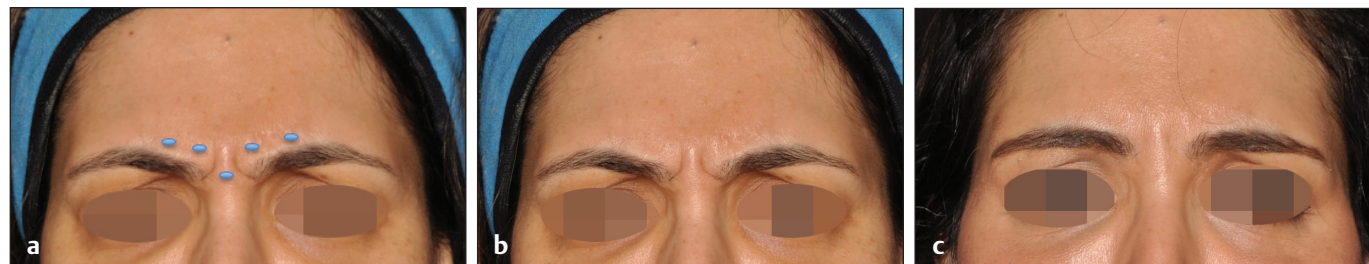### Browlift and Reshaping

A detailed knowledge of muscle anatomy is necessary to perform this advanced indication of toxin (**Fig. 8.2**). Carruthers<sup>15</sup> in a study showed lateral, then medial and middle eyebrow elevation by injecting 20 to 40 U of toxin in the glabella alone. Injection into the orbicularis oculi muscle at various points in the brow can give a browlift by relaxing the orbicularis oculi muscle at those specific points, thereby allowing the frontalis to elevate that part of the brow (**Fig. 8.3a, b**). By manipulating these points we can modify the shape of the eyebrows to our advantage. Horne and Rohrer<sup>16</sup> described central eyebrow elevation by selectively treating the inferomedial and lateral frontalis, allowing the central part to arch up. Ahn et al<sup>17</sup> injected at three points in the lateral brow and produced an average of 4-mm elevation of lateral brow. While attempting the eyebrow lift in men, if at all needed, care should be taken to keep the shape horizontal, or it will appear feminized.

### Forehead Lines

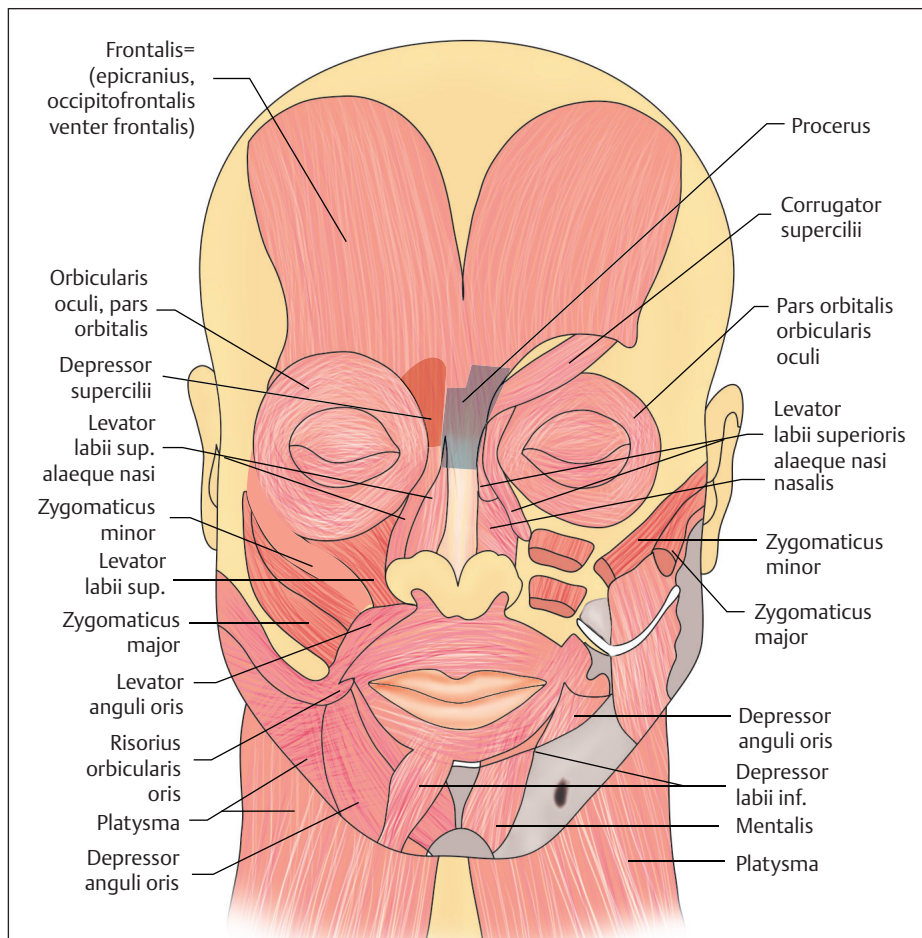
Injection of Botulinum toxin can alleviate dynamic lines, but also mild resting lines, improving with each successive injection.<sup>18</sup> When injecting the forehead for horizontal lines, all injection points must be at least 2 cm above the orbital rim (**Fig. 8.4a–d**) to prevent brow ptosis. Injection of 10 to 20 U in women and 20 to 30 in men had been originally recommended. However, in a consensus meeting<sup>18</sup> recommendations were made to reduce dose to almost half of that being used earlier, to get a more natural look. However, it was also recommended to follow up at 2 weeks to determine the need for further treatment. A Global Aesthetics consensus meeting in 2016<sup>19</sup> recommended a combination of toxin and fillers as the optimal treatment of forehead lines. Indian Consensus guidelines<sup>7</sup> however recommend a dose of 6 to 8 U in women and 10 to 12 U in men, with addition of fillers for static lines.

Relaxing of the medial frontalis muscle can lead to a hyperactive lateral edge of the muscle, causing the eyebrows to “spock”, which is easily treated by injecting 2 U of BontA in the hyperactive area 2 cm above the brow (**Fig. 8.5a, b**).

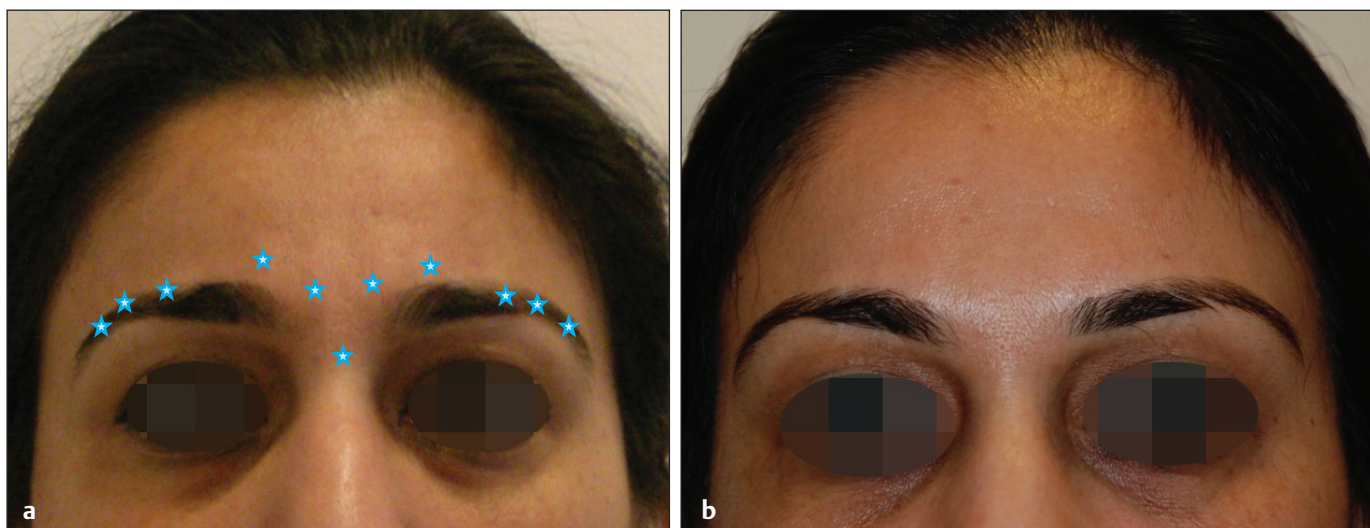


**Fig. 8.1** Patient desired improvement in glabellar complex but did not want a frozen expression. **(a)** Twenty units of Onabotulinum A injected into the procerus and corrugator muscles distributed over five points, 4 U per point. **(b)** Before injection, and **(c)** effect at 2 weeks showing a relaxed procerus and corrugator muscles with consequent improvement in the appearance.



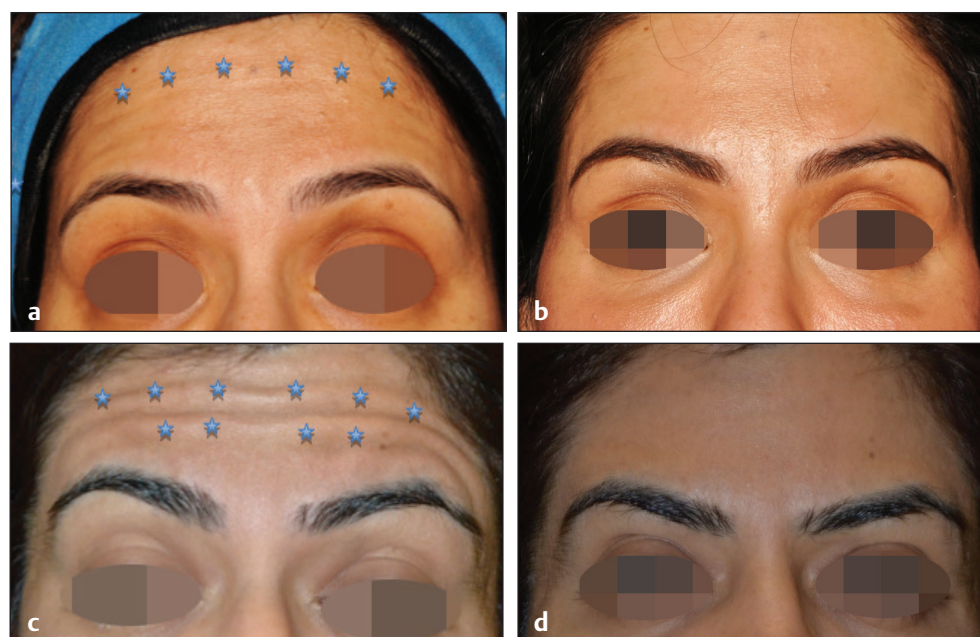

**Fig. 8.2** Muscles of the face, highlighting the upper face target muscles for Botulinum toxin. inf, inferioris; sup, superioris.

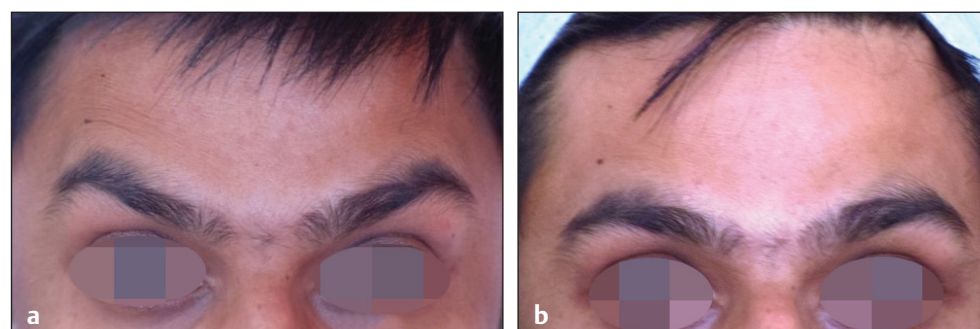


**Fig. 8.3** Eyebrow lift and reshaping. **(a)** Injection is done in the glabellar region as well as the points where the eyebrow needs to be lifted. Five points in the glabella (as described in **Fig. 8.1**), and three points in the eyebrow, 2 U each 1 cm apart as shown, placed subdermally to block the orbicularis oculi brow depressor action at specifically those points, allowing the frontalis to lift. **(b)** Postinjection after 14 days showing lowering of medial eyebrow and elevation of mid and lateral brow.





**Fig. 8.4** Treatment of forehead horizontal rhytides. **(a, c)** Inject 8 to 12 U of botulinum toxin A into the frontalis at multiple points (usually 6–10). These patients have also had glabellar lines injected. **(b, d)** Post-treatment with botulinum toxin A.



**Fig. 8.5** Spocking of the eyebrows caused by a hyperactive lateral frontalis. **(a)** Spocked eyebrows, **(b)** treated by 2 U of BontA 2 cm above the spock in the lateral frontalis.

Caution: In older patients, preexisting conditions like dry eyes or post-Lasik surgery status may precipitate/worsen dry eyes after BontA treatment.

### Periorbital Area

The periocular region shows signs of aging in the form of under eye dark circles, compounded by volume loss with eyes appearing sunken, or visible tear troughs. In addition, there may be brow ptosis, hooding of the eyelid as well as presence of lateral hyperdynamic lines called crow's feet (**Fig. 8.6**). Commonly in younger people, the last one may be the only problem present. Some people have hypertrophic pretarsal orbicularis (eyelid roll), which may cause eyes to narrow or shut completely during smiling (**Fig. 8.7**). Also, there may be lines in the infraorbital region extending from the medial limbus to crow's feet, known as infraorbital rhytides.

#### Crow's Feet

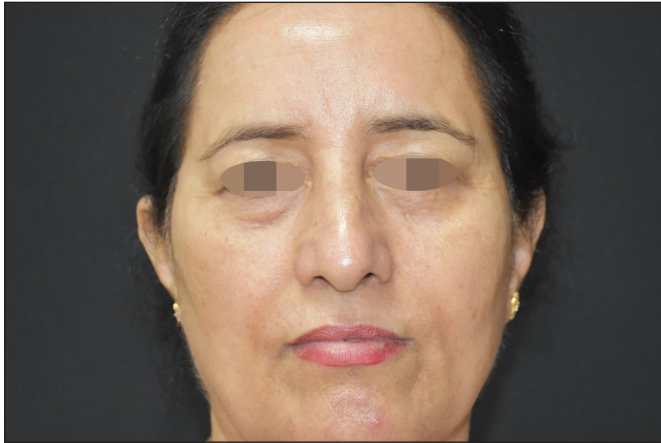It is advisable always to seat the patient upright with head supported and hair safely out of the way with a hairband. In the periocular region we inject subdermally (as the

orbicularis is adherent to the undersurface of the skin in this area with very little s/c fat) raising a bleb, at least 1 to 1.5 cm away from the lateral orbital rim. Usually three such injections are made in the upper, middle, and lower crow's feet lines. Visible veins in the area should be avoided to prevent/minimize bruising. A second row may be injected 1 cm lateral to the three points, if crow's feet are marked and extend laterally (**Fig. 8.8a**, with red dots indicating an optional second row). Six to twelve units of Onabotulinum A are recommended on either side<sup>7</sup> (**Fig. 8.8a**).

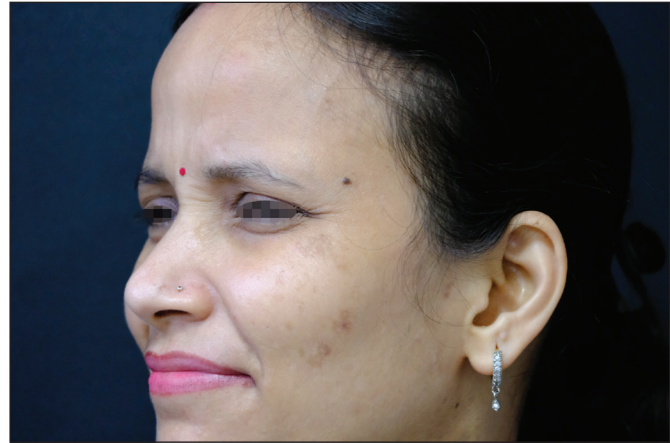A word of caution against chasing crow's feet into the cheek. Considering that the inferolateral part of the orbicularis oculi is the only cheek elevator, it can cause problems with smiling. Also, if we go beyond the zygomatic bone into the cheek, we may inject inadvertently into the main elevator of the angle of mouth, the zygomaticus major muscle, causing a drop in the level of the angle of mouth, with resultant asymmetry if it is unilateral.

#### Hypertrophic Pretarsal Orbicularis

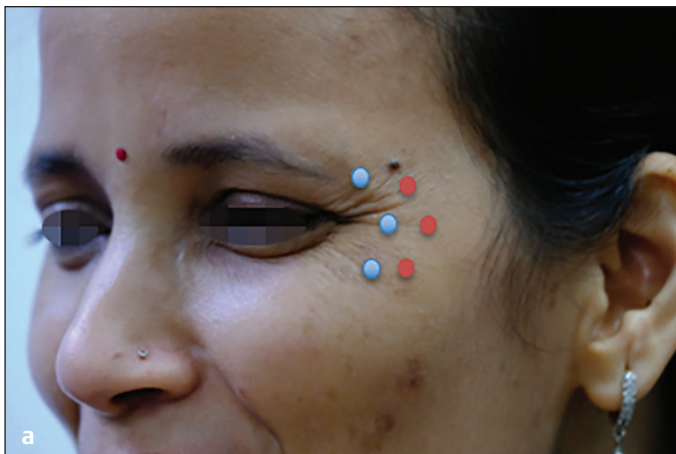This causes eyes to close while smiling, can be treated with 1 to 2 U of Botox in the midpupillary line 3 mm below lash



**Fig. 8.6** Aging changes in the periocular area.



**Fig. 8.7** Eyelid roll in a younger person.



**Fig. 8.8** Injection points for periocular rhytides (crow's feet), pretarsal roll, and infraorbital lines. **(a)** Three points (blue dots) BontA into the lateral orbicularis oculi muscle, 6 to 12 U per side (total of 12–24 U) depending on the severity of wrinkles; red dots indicate an optional second row. **(b)** Injection point for pretarsal roll in the midpupillary line 3 mm below lash margin, and infraorbital crow's feet point 7 mm from lash margin, between midpupil and lateral canthus.

margin<sup>20</sup> (**Fig. 8.8b**). Likewise, hyperactive infraorbital orbicularis can be treated with an additional 2 U about 7 mm below lid margin midway between the midpupil and the lateral canthus (**Fig. 8.8b**). Flynn et al in 2001 compared 2 U in the lower eyelid midpupillary line alone, with 2 U in midpupillary line plus 3 points in the crow's feet. Both resulted in widening of the eye, but the latter was more effective.<sup>21</sup> It is not advisable to treat orbicularis near the medial canthus, to avoid inhibiting the action of the lacrimal pump leading to epiphora.

### Adverse Effects

Bruising is a common adverse effect, which can be prevented by avoiding visible veins. If there is bleeding from the injection point, give gentle pressure for 5 minutes, with instructions not to exercise, or bend head forward and downward for 24 hours. An ice pack will help minimize the bruising.

Other common adverse effects in the glabella, forehead, and brow regions possibly are edema, headache, brow ptosis, and upper eyelid ptosis. A 5.4% incidence of blepharoptosis (upper eyelid ptosis) has been reported in a multicenter study by Carruthers in 264 patients, declining to 1% in a subsequent study.<sup>5,7,22</sup> It is important that while injecting the glabellar region, one should inject the lateralmost point of the corrugator very superficial (just subdermal), and staying at least 1 cm above the orbital rim for prevention of lid ptosis (**Fig. 8.3a**). It is presumed to occur because of diffusion of toxin along the supraorbital notch (following the superior ophthalmic vein) to the levator palpebrae superioris, or in the preperiosteal plane.<sup>23</sup> Ptosis appears at about 7 days after injection. Usually treatment is conservative as it resolves spontaneously in 2 to 3 weeks. Apraclonidine 0.5%,<sup>24</sup> phenylephrine 2.5%, naphazoline 0.05%, and brimonidine 0.2%<sup>25</sup> eye drops have been used with varying degrees



of success. The risk of using these eye drops in older people, especially those with a narrow gonial angle, is of precipitating acute narrow angle glaucoma.

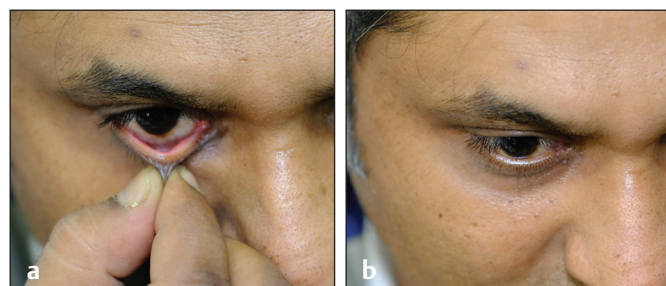
Brow ptosis has been seen following injection of forehead lines within 2 cm of the eyebrows, blocking the action of the lower frontalis. Treatment is to inject the 3 points described earlier to elevate lateral brow.

Injections in the periocular region should be done very cautiously in the elderly, as they have dry eyes, a lax lower eyelid, and a lax orbital septum. A lower eyelid snap test will give an idea of preexisting laxity of the lower eyelid. Performance of a snap test and testing for a dry eye are mandatory requirements before planning injections in this region. In patients with lower eyelid eye bags, injection into the preseptal orbicularis would result in aggravating the eye bags<sup>26</sup> and even appearance of festoons<sup>27</sup> due to relaxation of the preseptal orbicularis, whereas in patients with a positive snap test, injection of toxin would cause paralytic ectropion and epiphora, if the lower eyelid pretarsal orbicularis is treated (**Fig. 8.9a, b**).

Lip ptosis<sup>28</sup> or sometimes even cheek ptosis (the lateral orbicularis oculi functions as an accessory cheek elevator)<sup>29</sup> can occur in less than 1% of patients, and could be due to diffusion/injection into the inferolateral orbicularis oris fibers,<sup>29</sup> or the zygomatic muscles. This usually resolves in 2 to 3 weeks, but can also be helped by weakening the angle depressor (2 U into the DAO) on that side, thereby allowing a weakened elevator to lift the angle of mouth and the cheek.

## Midface

Anatomy of the midface is different in many ways from the upper face. The skin is tighter, muscles are more densely adherent, and wrinkles are often static than dynamic. The muscles of the midface are closely interdependent on the muscles of the lower face. Much lower doses of botulinum toxin are used in the midface and lower face than in the upper face. Adverse effects easily occur in the midface due to disturbance in the interbalance of muscles, rather than just by diffusion which is mostly the case in the upper face. In many areas of the midface, better results are obtained by fillers, use of energy-based devices, and invasive procedures like rhytidectomy. The commonly injected areas in the



**Fig. 8.9** (a) Snap test to determine laxity of the lower eyelid. (b) Quick return to normal position indicates a negative test.

midface are the scrunch or “bunny” lines, a dynamic drooping nose tip, and correction of a gummy smile.

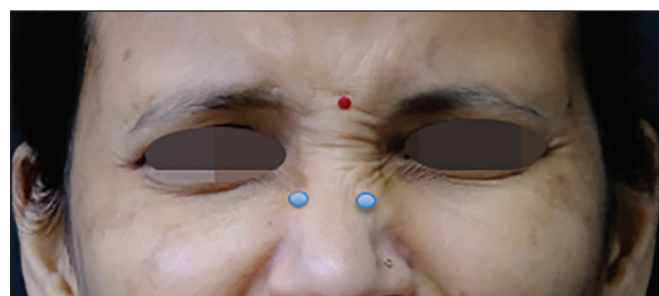
## Scrunch Lines

These are oblique lines in the upper part of the sides of the nose caused by contraction of the nasalis muscle. They may be present *de novo* when they are called bunny or scrunch lines, or appear after correction of glabellar lines as a compensatory mechanism (called “Botox sign”). Scrunch lines are treated at the same time as the glabella.<sup>30</sup> The lines are produced by the contraction of the transverse fibers of the nasalis muscle. If hyperactive, and not treated initially with the glabella, then will need to do so in the follow-up visit at 2 weeks. Injection is done at a point on the nasal bones on their side away from the angular vessels and the levator labii superioris alaeque nasii (LLSAN). Two to four units are injected on either side<sup>19</sup> (**Fig. 8.10**).

## Nasal Tip Ptosis

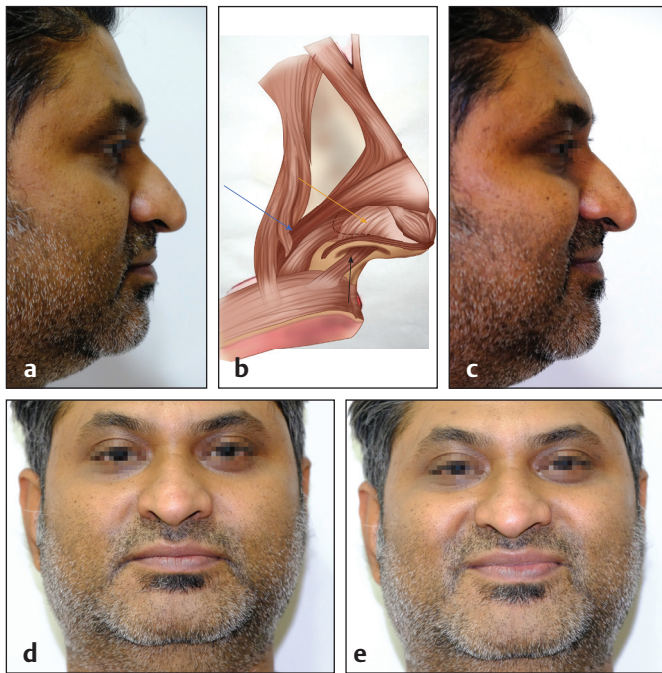
Dynamic nasal tip ptosis is when the nasal tip rotates downward while talking, depressing the upper lip or smiling. It is because of the action of a hyperactive depressor septi (DS) muscle. It can be associated with a short upper lip, transverse crease across the upper lip, or a gummy smile. DS arises from the region of the anterior nasal spine (ANS) and inserts into the caudal border of the cartilaginous septum, some orbicularis fibers, and along the nasal mucosa under the ala. In some people the LLSAN fires simultaneously to pull the alar base upward and backward, facilitating the rotation, and causing a gummy smile (**Fig. 8.11**).

The treatment of this dynamic nasal ptosis is to inject 2 to 4 U of Botulinum toxin A just above the labiocollumellar junction. Two additional units may be injected in the columella, with supplemental doses of 2 U in each dilator naris (into each alar rim in its middle), a total of 3 to 10 U.<sup>19</sup> And if the LLSAN is hyperactive, pulling the ala backward and upward as well as causing a gummy smile, it is advisable to simultaneously inject toxin 2 U in the LLSAN on either side as for a gummy smile<sup>31</sup> (**Fig. 8.12a, b**).



**Fig. 8.10** Scrunch (bunny) lines (more prominent on the left side) and the points to be injected for correction with BontA toxin. Also, we can clearly observe the contracted glabella, transverse facial lines caused by contraction of the procerus, and pretarsal hypertrophic orbicularis (lower lid rolls).





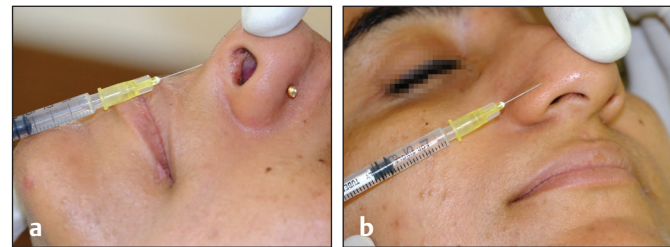
**Fig. 8.11** The dynamic drooping nose tip **(a)** in repose, **(b)** showing muscles responsible: levator labii superioris alaeque nasii (LLSAN) (*blue arrow*), dilator naris (*yellow arrow*), and **(c)** Smile firing up all three muscles. **(d)** Frontal view in repose. **(e)** Frontal view smiling with drooping tip, dilated nostrils, and pulled-up alae.

### Gummy Smile

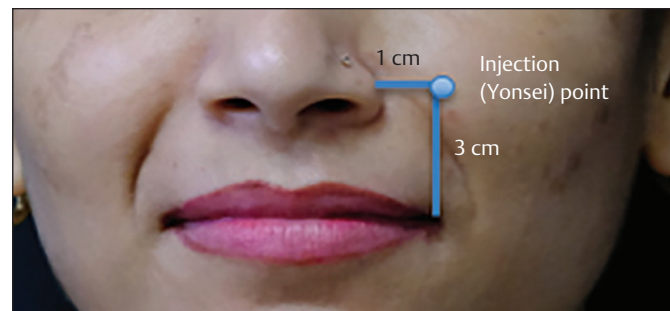
Excessive show of gums during smile or laugh is called a “gummy smile.” It is frequently associated with a short furrowed upper lip, and in some people a dynamic drooping tip of nose, occasionally all three features at the same time. Optimum tooth exposure has been assessed to be full crown height of the central incisors and 2 mm of upper gingiva.<sup>32</sup> Women generally show more gum than men who prefer a half-incisal show. Reasons for a gummy smile include an increased interlabial space, excessive contraction of upper lip elevators, often in combination with a genetically short upper lip, decreased upper incisor crown height, and increased vertical height of the maxilla. Four types of gummy smile have been described: anterior, posterior, mixed, and asymmetric, and different injection techniques recommended for each type.<sup>33</sup>

Those with gummy smile caused by hyperactive elevators of the upper lip are ideal candidates for Botulinum toxin A treatment. If cephalometry reveals normal dimensions, and 2 mm of upper incisor is seen in repose, then it is presumed that exposure of excess gingiva is due to hyperfunctional muscles.

Hwang et al in 2009 described the “Yonseil point” where all three muscles meet (LLSAN, LLS, and zygomaticus minor), which is about 10 mm lateral to the alar base and 30 mm



**Fig. 8.12** Injection technique for dynamic drooping nose tip. **(a)** Depressor septi muscle being injected after lifting the tip of the nose away from the orbicularis. **(b)** Additional units being injected midway on the alar rim into the dilator nares.



**Fig. 8.13** Injection point described as the Yonseil point by Hwang et al in 2009 as the confluence of three muscles: levator labii superioris alaeque nasii (LLSAN), levator labii superioris (LLS), and zygomaticus minor.

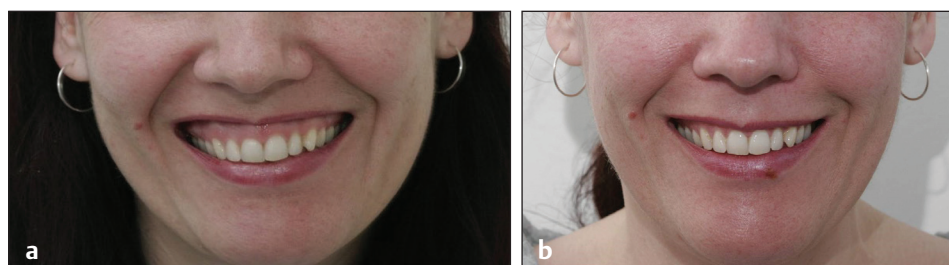above the horizontal lip line. Here the muscles are subdermal and dose of Botox required is less.<sup>34</sup>

Benedetto<sup>30</sup> recommends 2 U of toxin in the alar-facial groove into the palpable LLSAN just over periosteum. If the central gingiva is exposed more, then 1 U is injected in the DS. Another method described by Polo<sup>35</sup> is to inject 1 to 2 U in the central lip elevators given transmucosally. Polo<sup>35</sup> injected 2.5 U each at 2 points per side, first at the Yonseil point, and the second 2 cm lateral to it, only if the gummy smile extended laterally<sup>33</sup> (**Fig. 8.13**). He achieved a mean lowering of lip by 5.1 mm at 2 weeks. Effect lasts for 3 to 6 months.<sup>35</sup> **Fig. 8.14a, b** shows a young lady with a gummy smile with no malocclusion, only hyperactive elevators, which is the right indication for Botulinum toxin A.

### Adverse Effects

While injecting “scrunch lines,” if the injection is too lateral or low, we can get asymmetry and ptosis of the upper lip, or even epiphora from diffusing into medial orbicularis fibers.<sup>30</sup> Hematoma can result from puncturing of the angular vessels.

In case of injections for the “drooping tip of the nose,” only dynamic drooping tip will respond to injection. Diffusion from injecting the DS can affect the upper lip elevators and the sphincteric action of the orbicularis causing upper lip



**Fig. 8.14** Gummy smile and its treatment. **(a)** Lady with gummy smile from hyperactive lip elevators. **(b)** After 2 U of botox at the Y point.

lengthening, thinning, effacing of the philtrum, asymmetry, and difficulty with eating, swallowing, and speaking.<sup>36</sup>

On the other hand, treating the gummy smile, the risk of producing asymmetry is high, and high doses here are likely to produce upper lip ptosis and incompetence of the oral sphincter with its attendant problems.

The key is that in the midface, only experienced injectors of toxin can safely venture, as due to extensive interdependence of muscles, risk of diffusion into adjacent muscles is high.

Therefore, the doses need to remain small, and no massage should be done post injection.

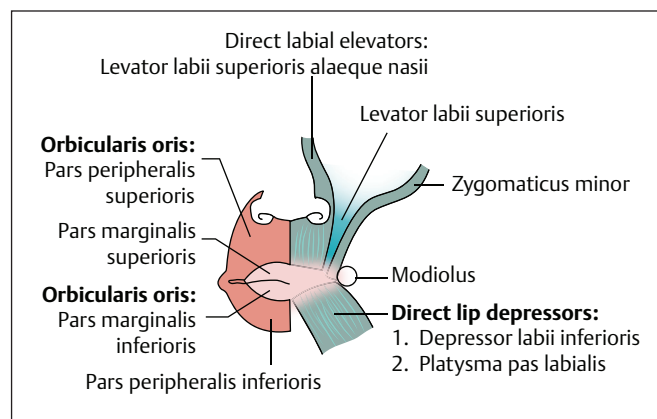
## Lower Face

The orbicularis oris muscle, the depressor anguli oris (DAO), depressor labii inferioris (DLI), mentalis, and the platysma muscles are responsible for the complex movements in the lower face. Aging affects them by increased resting tone and repetitive movements causing a crease/creases, and also by underlying bony resorption. Marionette lines are thought to result from DAO hyperactivity, assisted partly by bone and fat resorption, plus gravity pulling down lax tissues. The hyperactive mentalis muscle accompanied by bony absorption in the chin region also leads to an upwardly displaced chin eminence and a popply chin (**Fig. 8.10**).

Excessive blocking of perioral muscles will cause issues with speaking, whistling, and expression. Therefore, mild, functional blocks are needed. It is preferable to have a lesser dilution of the reconstituted BontA solution to minimize diffusion in this area.

### Perioral Lines

They form as a result of repetitive actions of the orbicularis oris muscle such as in smoking, habitually pursing lips, playing particular wind instruments, and these usually occur in women. Men develop them less due to presence of beard hair preventing inward turning of skin. Also, women have problems of lipstick bleeding into these grooves all the time. Perioral lines are also worsened by aging and prolonged sun exposure causing thinning of the skin. Dynamic perioral lines will respond better to botulinum toxin, whereas static lines will benefit from a combination approach with fillers as well as using a fractionated laser like CO<sub>2</sub> as adjunctive therapy.



**Fig. 8.15** Anatomical parts of Orbicularis oris muscle and its relationship with various muscles of the face.

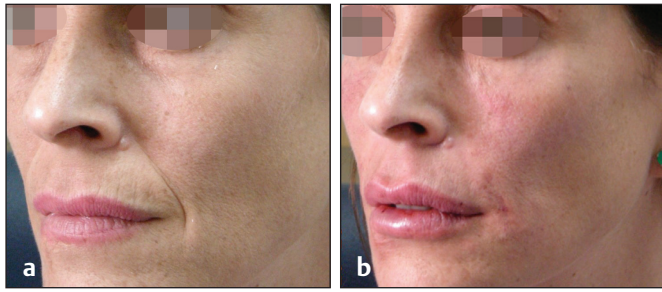
The orbicularis oris is a complex muscle with intrinsic (deep) and extrinsic (superficial) fibers. There is also crisscrossing of fibers from above down and vice versa. The superficial fibers are divided into pars marginalis (in the vermillion) and pars peripheralis (in the skin part). Each is divided into four parts: right and left, upper and lower. The peripheralis arises mostly from the modiolus where the elevators and depressors contribute (**Fig. 8.15**).

### Technique

Perioral lines need 1 to 2 U of toxin to be injected very superficially raising a bleb, just above the white roll at 2 points on either side of the midline in the upper lip, and 1 point on either side in the lower lip.<sup>36</sup> The objective being only to inject the superficial fibers, and maintaining symmetry to prevent any resultant functional asymmetry. Addition of HA fillers in the lines will help smoothen out the rhytides (**Fig. 8.16a, b**). Lipstick running out into the skin is best corrected by injecting fillers (not BontA) in a linear manner along the white roll.

### Marionette Lines

Marionette lines extend from below the angles of the mouth downward and outward till the lower border of the mandible ending in the prejowl sulcus. They are also called the labiomandibular groove and give the impression of sadness and disapproval. They are usually caused by a hyperactive DAO muscle which is a triangular muscle originating from



**Fig. 8.16** Combination treatment of perioral lines. **(a)** Static perioral lines in the upper as well as lower lip running across the vermillion border causing lipstick bleed. **(b)** After 4 U of toxin followed by hyaluronic acid (HA) filler after 2 weeks in the lines as well as vermillion border and volume increase of the lip.

the posterior part of the oblique line of the mandible superficial to the DLI muscle. It converges and inserts into the modiolus, with some fibers decussating with the orbicularis oris, risorius, levator anguli oris, and inferiorly posterior fibers with the platysma (**Fig. 8.17**).

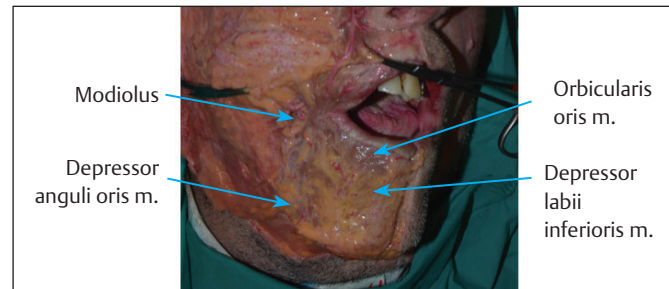Injection of BontA is safely done by keeping closer to the mandibular border on a line dropped from a point 1 cm lateral to the angle of mouth, thus injecting into the lower third of the muscle near its posterior border (**Fig. 8.18**). One can start with 2 U the first time, and then increase in subsequent injections up to 4 U/side. This helps improve the smile in people having excessive downturning of the angle of mouth, as well as partly smoothen out marionette lines. In addition, an extra point can be injected at the lower border of the mandible where its posteriormost fibers meet the platysma. Injection should be kept superficial as it overlies the DLI muscle.

Most older patients will require volume support with filler under the angles of the mouth, often extending all the way to the prejowl sulcus to simultaneously correct loss of soft tissue support in the area. Poor dental support caused by loss of teeth also contributes to this, and should be kept in mind (refer to the section on fillers).

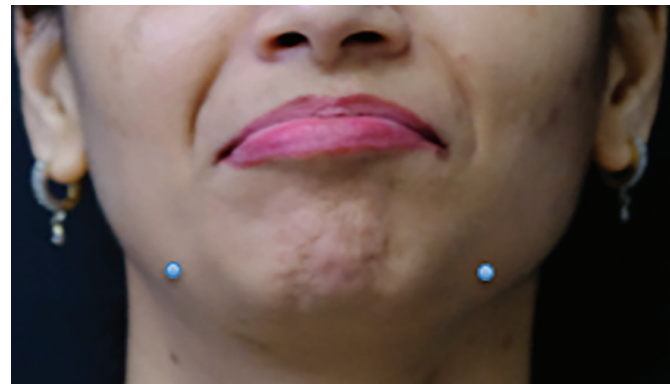
### Puckered or “Popply” Chin

In a lot of people both men and women, mostly the latter, contractions of a hyperactive mentalis cause a puckering of the chin—localized or generalized across the front of the chin. Many people involuntarily keep puckering their chin, but in the elderly where there is resorption of the bone in the chin area, a hyperactive mentalis causes the chin to ride upward in the front of the mandible. This can be well brought out by making the surprised look action with eversion of the lower lip.

The paired mentalis muscles arise from either side of the midline from the incisive fossa and insert into the skin of the front of the chin over a wide area. In a cleft chin the fibers do not meet in the midline. Some fibers also decussate with the



**Fig. 8.17** Cadaver dissection showing muscles of the lower thirds of the face and the modiolus, muscle.



**Fig. 8.18** Injection points for the depressor anguli oris.

orbicularis in the upper part and with the DAO laterally. It elevates the chin, causes chin of the front of chin to pucker, and helps in eversion of the lower lip.

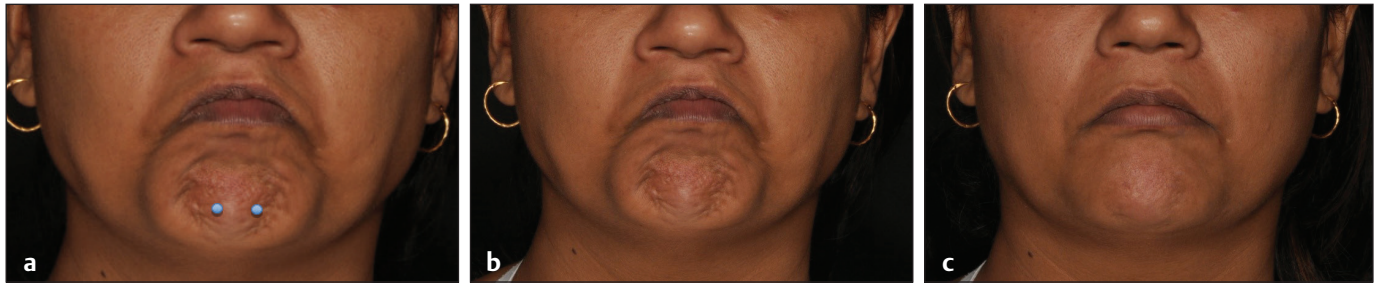Toxin injection into the mentalis is used to treat chin dimpling, as well as helping the chin not ride upward while speaking, which gives an impression of decreased vertical height of the lower third of face, as well as increasing depth of the labiomental crease. Usually 2 to 4 U of botulinum toxin is injected in 2 points deep into the muscle in front of the mental protuberance.<sup>36</sup> This is adequate if the chin is cleft, or wide and square. However, in a narrow and pointed chin, this may lead to diffusion laterally into the DLI muscle, and therefore many people prefer to inject 4 U in a single point in the midline in the lower half of the muscle (**Fig. 8.19a-c**).

A popply chin might require diluted toxin to be injected very superficially at multiple points. Fillers may be required after 2 weeks to improve chin position and contour, as well as to efface the labiomental groove. BontA injection is preferably made in the chin prominence at one point in the midline or at 2 points very close to the midline to avoid lateral diffusion into the DLI (**Fig. 8.19a-c**). A popply chin may require a more superficial injection with very diluted BontA strength.

### Adverse Effects

Injection of toxin into the perioral lines can cause difficulty in speaking, whistling, pouting, or blowing which usually lasts for a few days in almost every patient. However, if higher





**Fig. 8.19** (a) Hyperactive mentalis causing severe puckering of the chin in a wide square chin. Three to four units of toxin is injected at each of the two points deep into the muscle. (b) Pretreatment picture showing the puckering caused by an active pair of mentalis muscles. (c) Posttoxin and hyaluronic acid (HA) filler to chin. Four units of botulinum toxin A were injected into the mentalis muscle in the midline followed 2 weeks later by HA filler injection in the chin area.

doses are injected, all these symptoms become more severe and persist till the effect goes away. Also, drooling can occur in some cases. Injection into the philtrum is avoided as it results in flattening of the same. The points to be injected should be symmetrical and equal in dose, otherwise asymmetry can result. Orbicularis oris is the only inverter of the lips, and paralysis can lead to loss of sphincter control as well as difficulty in pronouncing bilabial sounds, making public speaking difficult.

The DAO is another muscle where one can easily get into trouble by injecting close to the DLI especially in the area where fibers of muscles overlap as they both originate from the oblique line of the mandible. Since the DLI lies deeper and partially anterior to the DAO, the injections should be kept superficial and in the posterior and inferior parts of the DAO. If toxin diffuses into the DLI, it produces a classic deformity caused by inability to pull the affected half of the lip downward while speaking (**Fig. 8.20**).

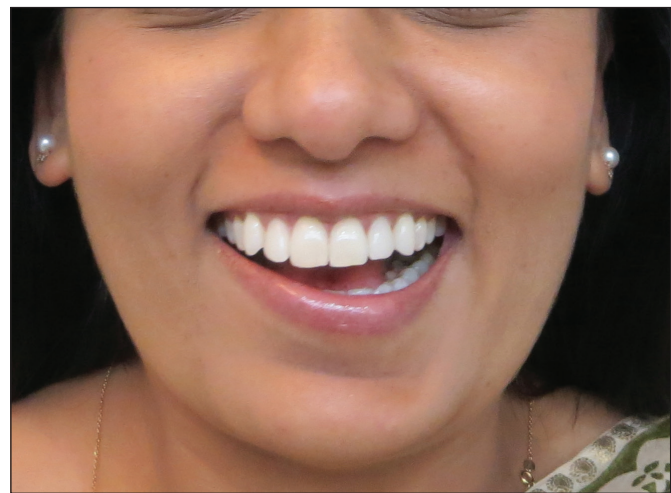When the mentalis is injected at two points, one should be careful about diffusion into the DLI laterally, or the orbicularis upwards. Massage of the chin should especially be avoided, to avoid dispersal of toxin. Too high a dose can lead to dribbling of liquid while drinking.

The DAO, DLI, and the mentalis are all evertors of the lower lip.<sup>37</sup> If we manage to block all three, the DAO and mentalis by design, and the DLI by accidental diffusion, it can cause severe inversion of the lip along with involuntary biting of the lower lip and buccal mucosa.

While injecting the lower face we should take note that the lower face muscles are small, thin, of lower mass, and so need less toxin to show response. They are not forgiving when overdosed and can easily result in complications.

## Injectable Fillers

Fat was one of the earliest fillers used in the face, which has gradually evolved into microfat and nanofat transfer, refueling interest with the current body of work in stem cells. Collagen as a filler was widely used in the 1980s and 1990s but its limitation was the short duration of effect (3–4 mo),



**Fig. 8.20** Botulinum toxin A injection into the depressor anguli oris (DAO) on the right side has diffused into the right depressor labii inferioris (DLI) causing lower lip to remain up while smiling. (The image is provided courtesy of Dr Chytra Anand, Bengaluru, Karnataka, India.)

and its delayed hypersensitivity. Collagen as a filler occupied pride of place till the Hylan (hyaluronic acid) gels came in.

In 2003, Restylane was the first HA product to get FDA approval. HA was discovered at Columbia University by Karl Meyer and John Palmer.<sup>38</sup> They isolated it in bovine vitreous humor in 1943. HA is a polymer of disaccharides composed of D-glucuronic acid and DN-acetyl glucosamine, which has widely been used as a filler to treat rhytides, folds, and volume loss in recent times. HA acts as a scaffold for elastin and collagen, is hydrophilic, and can hydrate the skin. As we age, the naturally existing HA in our skin decreases, thereby leading to loss of volume, elasticity, and turgor of the skin.

Initially, extracted HA was from animal sources, but the current source of production is bacterial (NASHA—nonanimal stabilized hyaluronic acid). Hyaluronic gel can be found as biphasic or monophasic types, latter being a homogenous solution. Medical-grade silicone (Silikon 1000) was introduced in 1997 for ophthalmic use, although off-label use was permitted by FDA.<sup>39</sup>

Poly-L-lactic acid (PLLA) (Sculptra) was approved for correction of fat atrophy secondary to AIDS. It needs advance dilution with sterile water, and about 3 (5–10 mL) injections over months, and lasts for 18 to 24 months. These properties have limited wider use of PLLA.<sup>40</sup>

Calcium hydroxyapatite was approved by FDA in 2006 for treatment of moderate-to-severe facial lines and folds and cheek volume loss from HIV-related lipoatrophy. It is 30% CHA particles suspended in saline. Carboxymethyl cellulose gel, lasts for about 1 year, and is biocompatible. As it is not possible to inject it superficially, not in lips, and is not reversible, it has limited appeal.<sup>41</sup> The future may well be a technique of injecting autologous fibroblast cultures to produce collagen locally<sup>42</sup> with early studies already showing promise.

The name “fillers” has stuck, because initially they were injected to just fill static lines and folds. It was a two-dimensional concept to begin with. But gradually with the evolution into a three-dimensional concept of the face, the idea of volumization took roots. With the discovery of the superficial and deep fat compartments by Rohrich and Pessa<sup>43</sup> and others after them, selective volumization of fat compartments of the midface evolved.

Later, it was the lower face where the concept was applied. The acceptance of the importance of volumization of the upper third of the face came the last. The temples began to be volumized, and now even the upper forehead and the suprabrow region in the forehead are recognized and treated for volume depletion. In fact, the treatment of glabellar frown with fillers is no longer promoted because of risk of vascular complications.<sup>44</sup> Recently, newer concepts like emotional attributes and myomodulation described by de Maio have evolved, which are changing the way fillers are being used currently.<sup>45</sup>

## Upper Third of Face

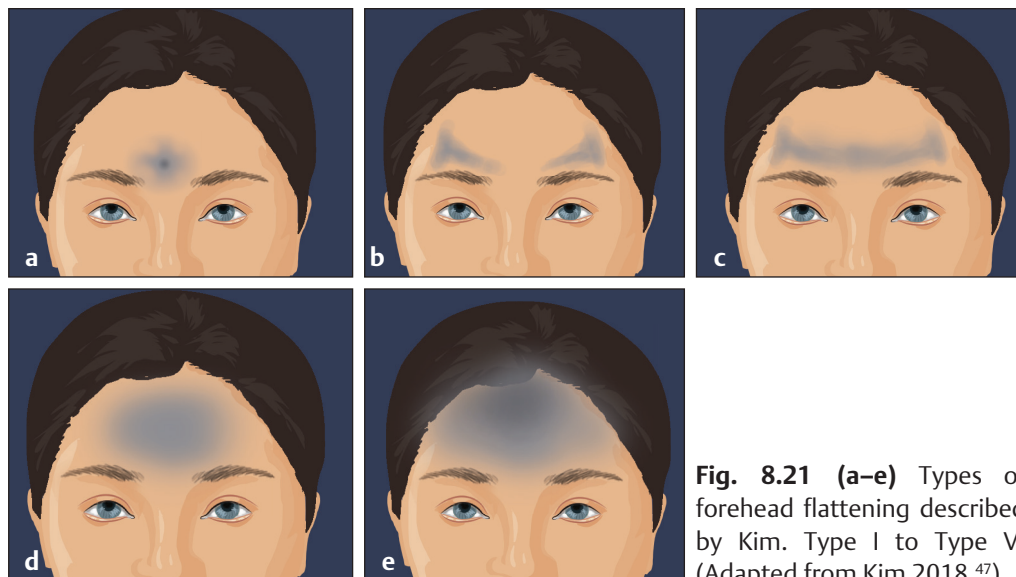
It was believed earlier that neuromodulators gave the best results in the upper third, but now all accept that a combined approach of toxin with injectable fillers gives the best result. Toxin is safer in the glabellar region. Static glabellar and forehead lines may require filler injection 2 weeks after toxin injection. Here a low G' filler is placed in the mid-dermis.

## Forehead and Suprabrow

There are patients who desire only fillers for the glabellar and the suprabrow region, and do not want any toxin. Also, where there are deep resting vertical or horizontal lines, one needs a neuromodulator, followed at 2 weeks by filler.<sup>4,19</sup> The glabellar region should be treated with caution with filler injections, as it is a high-risk area for vascular complications.<sup>44</sup>

Hollowing/flattening in the central glabellar region and/or suprabrow region (possibly from repeated BontA injections) will benefit from fillers. Asian patients mostly benefit from this, but Indians already having a larger forehead, along with a greater upper third to lower two-third ratio, may not frequently require volumization of the forehead.<sup>46</sup>

Kim<sup>47</sup> described five types of hollowing of the forehead to determine need and volume of forehead contouring with fillers. Type I is glabellar flattening (central depression), type II triangular suprabrow depression, type III is the transverse suprabrow hollowing across the lower forehead, type IV is all-round depression of the forehead, and type V is global-inclined slope forehead (**Fig. 8.21**). Using a 23/25-gauge cannula in the subcutaneous/subgaleal plane is safe, which gives optimal contouring. Access point could be in the midline 2 cm above the brow, or lateral hairline, or both in cases of Type V (**Fig. 8.22**).



**Fig. 8.21 (a–e)** Types of forehead flattening described by Kim. Type I to Type V. (Adapted from Kim 2018.<sup>47</sup>)

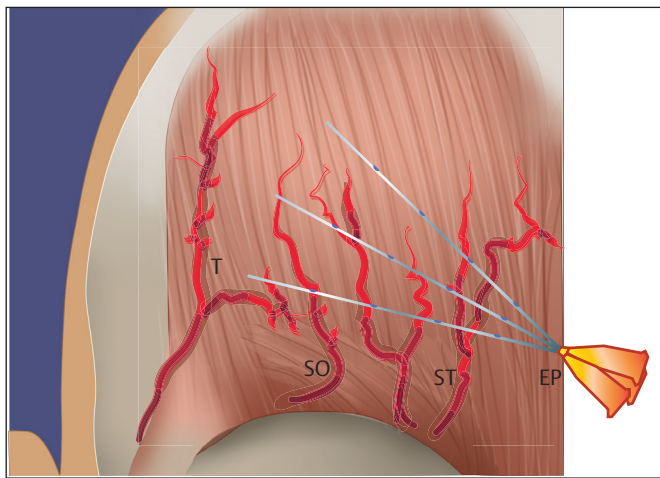
A medium/low-viscosity product like Voluma and Volift are ideally suited, whereas a high-viscosity product like Perlane is suggested to be diluted by Sundaram and Carruthers.<sup>48</sup> Superficial, subcutaneous injection at the suprabrow level is safe as the neurovascular bundle is deep here. A needle approach is preferred here as it is a tight plane. De Maio<sup>49</sup> has described a three-point forehead reshape (total six points) for medial, lateral, and central forehead filler injection, 2 cm above the brow using a cannula in the supraperiosteal plane with alerts for the supraorbital, superficial temporal, and supratrochlear arteries. Follow-up is necessary at 2 weeks.

### Complications

Lumpiness can result from using a product which is of a high  $G'$  and does not disperse well. Sometimes a sunburst appearance can result. Accidental intravascular injection into any of the three arteries described can cause blanching, which if left untreated can cause varying amounts of skin necrosis. Adhering to anatomy will possibly avoid those complications. If skin blanching is observed, a gentle massage will dissipate the filler and make the blanching go away. If not, then hyaluronidase can be used to remove filler till blanching goes away.<sup>50</sup>

### Periorbital (Periocular) Area

This includes the eyebrow, supraorbital rim, infrabrow region, upper eyelid, lower eyelid, infraorbital rim, lid cheek junction, lateral and medial canthal regions. It is not an area for new injectors. Assessment is very important. In patients with high cheekbones, it manifests mostly as volume depletion, whereas in patients of Indian ethnic origin with chubby cheeks and heavy poorly supported midface, it manifests mainly as skin excess.



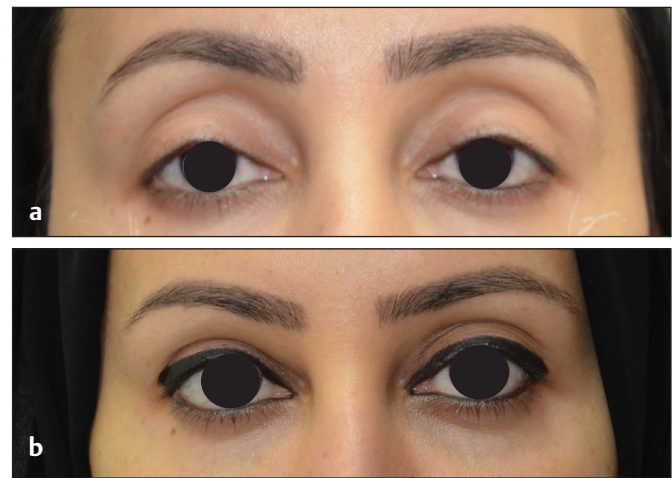**Fig. 8.22** Access point in the forehead for fillers, 2 cm above the eyebrow, midline, supraperiosteal using a 25-gauge 50-mm long cannula. (Adapted from Kim 2018.<sup>47</sup>)

Periorbital aging is due to tissue resorption and loss of skin elasticity. It manifests as ptotic and volume-depleted eyebrows, hollow infrabrow region (“A” frame deformity), skin laxity lateral to the lateral canthus, deep static periorbital rhytides, laxity in the upper eyelids, and skin excess with laxity and eye bags in the lower eyelids.

Assad et al<sup>51</sup> in a systematic review on eyebrow position changes with age found that in most studies medial and central brow were higher (due to compensatory frontalis action), whereas most found lateral eyebrow descent (due to absence of frontalis fibers in that area).

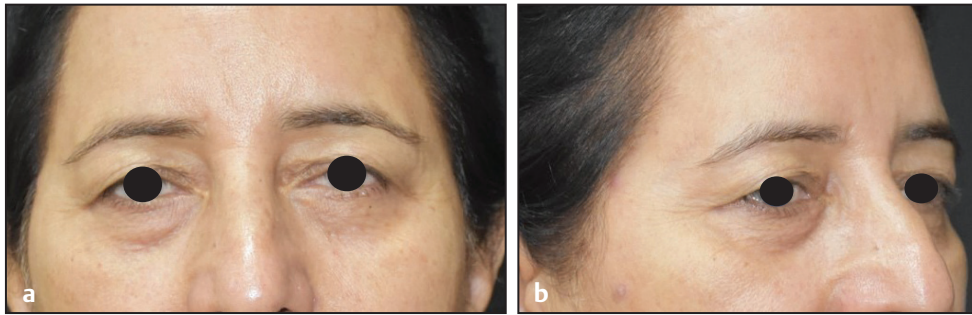
The infrabrow region shows consistent loss of fat leading to a gaunt appearance. In the eyebrow region most muscle is replaced by fat, leading to a ptotic brow and upper eyelid hooding and folds (**Fig. 8.23**).<sup>52</sup> The infrabrow region is a dangerous territory to tread on, and done incorrectly, one may achieve no improvement, or sometimes even make the area bulky and worse. The crow’s feet area is relatively safe, and post neuromodulators, some very low-viscosity filler may be required in the submuscular plane, as the skin is very thin here. We can use a needle or 25-gauge cannula in this area. De Maio<sup>49</sup> has described points for periorbital rejuvenation—E1, E2, E3 for the eyebrow, O1, O2, O3 for the lateral orbital region reshape, and Tt1, Tt2, and Tt3 for the infraorbital region (**Fig. 8.24**).

Usually a 25-gauge 40-mm flexible cannula is recommended, although many injectors use the needle at all points except E2, E3, and Tt3 points shown in **Fig. 8.25**. Very superficial placement of filler in this region may lead to a bluish gray tint called the “Tyndall effect” from light reflecting off a thick layer of the superficially placed filler. Usually the results with fillers are very gratifying in this area especially in the very aged skin where the majority of wrinkles are static.

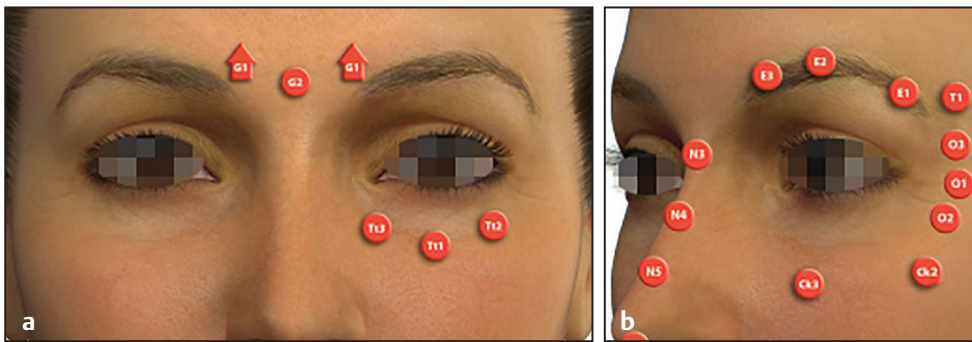


**Fig. 8.23** Early infrabrow hollowing (A-frame deformity) in a 29-year-old lady, genetic in origin and not due to aging. (a) Before and (b) after filler injection with a 25-gauge cannula.





**Fig. 8.24 (a, b)** Sixty-year-old female showing signs of periorbital aging: ptotic lateral brow, dermatochalasis upper lid, infraorbital skin excess with eye bags, and infraorbital hollowing. Temple hollowing and eyebrow volume depletion contributing to eyebrow descent.



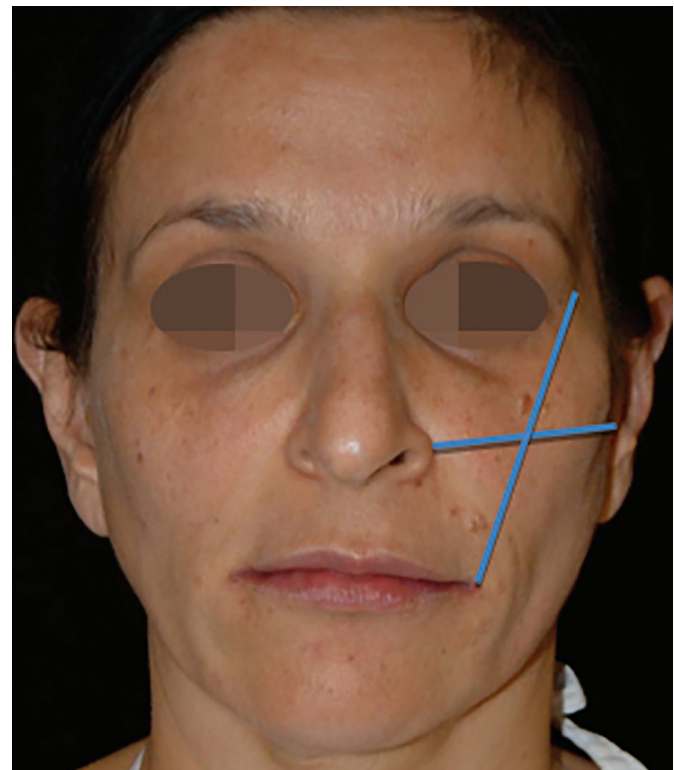
**Fig. 8.25 (a, b)** MD Codes points described by de Maio for periorbital rejuvenation. These are guidance points. (Adapted from de Maio 2020.<sup>49</sup>)

## Midface

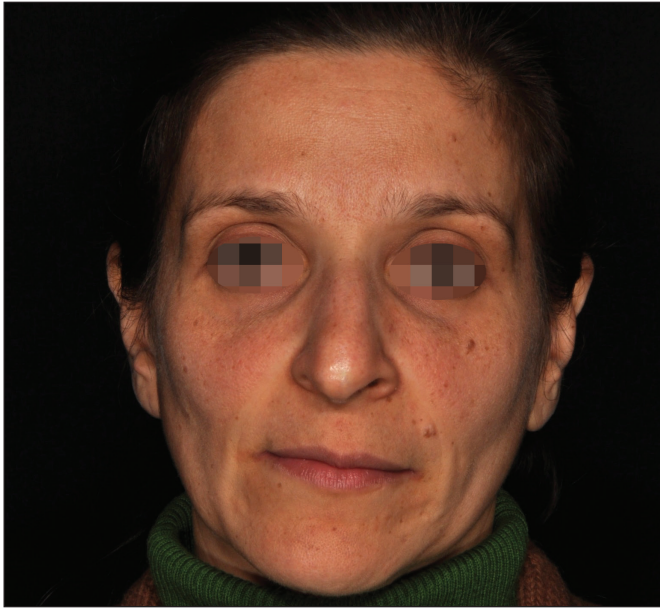
Treating the midface primarily involves treating the zygomaticomalar area (lateral cheek), the infraorbital region (medial cheek), and the tear trough. For the purpose of treatment, we can use as reference Hinderer lines on the face as shown in **Fig 8.26**.

In youth, the middle third of face has a convexity which progressively flattens with age. The convexity in the mid face is maintained by the malar fat pads supported by the zygomatic bones. According to Rohrich and Pessa<sup>43</sup> the **malar fat pad** is divided into three compartments—medial fat compartment of the cheek (superolateral to the nasolabial fat pad), and middle and the lateral temporal-cheek fat. The zygomaticomalar region contributes to the lateral projection on the face due to the projection of the zygomatic bone. In childhood, this part is not projected but it reaches maximum development in the second decade.

The lateral suborbicularis oculi fat (SOOF) and the malar fat pad are responsible for the projection of the most anterior part of the cheek. The aging of the adipose compartments have a central role in facial aging. Aging is happening because of both ptosis of soft tissues (fat and skin) and the hypotrophy of the deep fat compartment. The reduction of volume in the deep fat compartments leaves the overlying superficial fat compartments and skin unsupported. Loss of deep midfacial fat leads to loss of support for both the medial cheek fat and the lower eyelid, with unmasking of the infraorbital rim and the orbital fat. This also contributes to the exaggerated nasolabial folds (NLFs) (**Fig. 8.27**).



**Fig. 8.26** Hinderer lines divide the midface into four compartments: medial malar, lateral malar, submalar, and area superolateral to the nasolabial fold (one line is drawn from the tragus to the alar groove and another one from the lateral end of the eyebrow to the oral commissure).



**Fig. 8.27** The aging midface in a 47-year-old Indian lady. There is aging in four layers: bone, muscle, fat pads, and skin.

There are numerous retaining ligaments in the midface and attenuation of these ligaments with age also is known to contribute to ptosis of soft tissues. The zygomatic ligament is formed at the confluence of septa where all three compartments meet, and corresponds to the midcheek groove (**Fig. 8.28**).

The hollows appear where the ligaments are attached, and the bulges where the ptotic fat pads descend (**Fig. 8.28**). Pessa<sup>53</sup> has shown that with age there is a posterior inferior rotation of the skeleton toward the base of the skull. This reduces the bony support to the soft tissues, and happens much later in life.

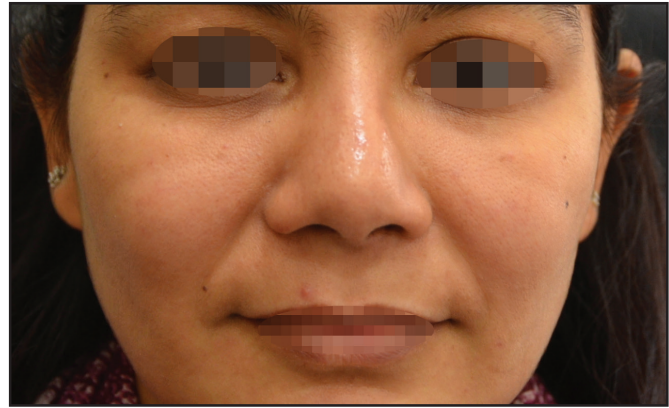
Skin laxity, ligamentous laxity, atrophy of deep fat compartments with simultaneous hypertrophy of superficial fat compartments, and later in life bony remodeling all contribute to aging of the face (**Fig. 8.27**).

### Tear Trough

The tear trough is a commonly seen facial feature in the Indian face, appearing sometimes in the teens, and which worsens as we age. It is an infraorbital depression starting at the medial canthus, and extending inferolaterally along the lower orbital rim and from the midpupillary point may continue into the nasojugal fold and more laterally into the midcheek groove. The tear trough is a significant area of concern in the Indian face. Majority of Indians suffer from varying degrees of tear trough because of anatomical considerations such as deep set eyes, recessed infraorbital rim, and deficient soft tissue support in relation to the lower eyelids.

### Technique

It is widely believed that the deep compartment of the midface should be volumized first, thereby lifting the cheeks



**Fig. 8.28** “Midcheek groove” seen in a young lady. It corresponds to the site of the zygomatic ligament, and is a continuation of the nasojugal groove laterally. “Tear trough” extends from medial canthus to midpupil, “nasojugal groove” from midpupil to lateral canthus, and “midcheek groove” beyond that.

to a varying extent, spontaneously improving the NLFs and bringing down the filler volume requirement of the tear trough and the nasojugal fold, as well as that of the NLF.

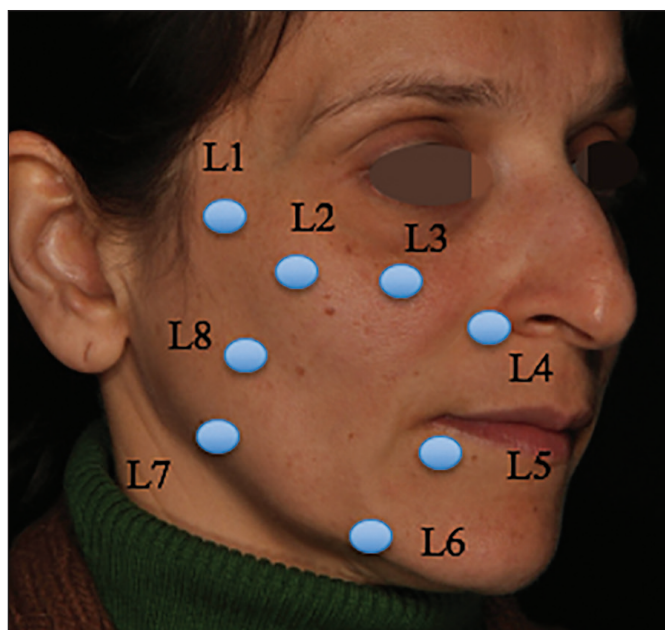
When volumizing with fillers, we can inject with needle or microcannulas. We can use the linear fan technique or give supraperiosteal bolus injections. Selection of the appropriate technique depends on various factors—the age of the patient, the degree of volume loss, quality of overlying skin, degree of skin laxity, area to be injected, vascular pattern in the area, possible risk of arterial complications associated with that region, and largely also depends on the skill sets of the injector.

In younger subjects, an eight-point lift has been described by Mauricio de Maio,<sup>54</sup> which provides boluses of filler in the zygomatic arch area, lateral malar and medial malar area, the nasolabial groove (upper one-fourth), below the angles of mouth for support, prejowl sulcus, angle of mandible, and the hollow buccal region (**Fig. 8.29**).

Patients who have very little skin laxity and mild degree of volume loss will benefit greatly from this technique, also at the same time economizing on the amount of filler used. However, this approach may not work in older patients with more volume loss and significant degree of skin laxity. In the latter, volume has to be primarily replaced in the deep fat compartments, and also borrow in addition, some of the points of the 8 point lift. Midface filling is easier with a single point in the lateral malar area entering the prezygomatic space, going up to the tear trough and the nasojugal fold (**Fig. 8.30**).

Pain relief is good with Xylocaine 2% with adrenaline at the point of entry of the cannula and a zygomaticofacial nerve block (placed on the summit of the zygoma), aided by lidocaine combined fillers. The tear trough can also be filled separately using a 25-gauge cannula entering from the midcheek area (**Fig. 8.31**).





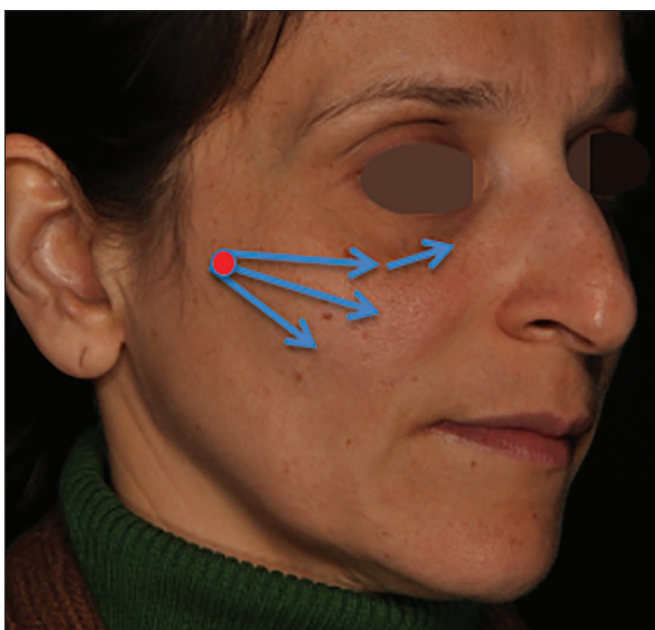**Fig. 8.29** Eight-point lift as described by de Maio. L1: zygomatic arch, L2: body of zygoma, L3: medial malar, L4: piriform fossa, L5: below oral commissure, L6: prejowl sulcus, L7: angle of mandible, L8: preauricular/buccal hollow.

It is preferable to treat the tear trough with a low- or medium-density filler placed supraperiosteally, deep to the orbicularis oculi muscle in the area of the SOOF. The most medial part of the tear trough is challenging to correct as the orbicularis muscle is attached to the bone with the medial-most part of the orbicularis-retaining ligament (ORL) called the tear-trough ligament and it is not possible to inject beneath it. Also, there is practically no fat support under the skin and skin quality is often compromised. In the tear-trough region there is a risk of overcorrection with fillers making the product visible and palpable. If the product is placed superficially it becomes visible as a bluish discoloration (Tyndall effect).

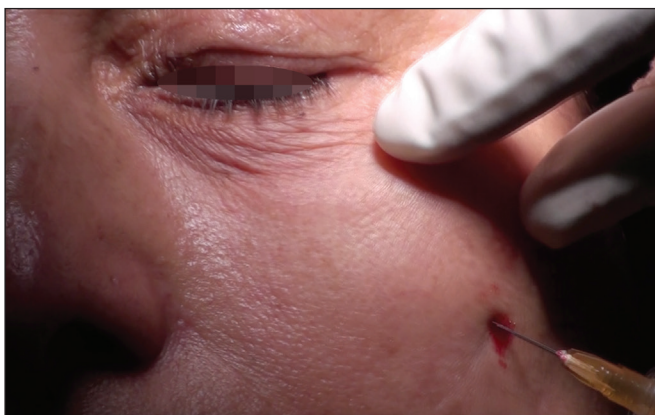If there are preexisting malar bags, then while correcting the tear trough, one may aggravate the malar edema. In such cases, one should avoid injecting into the medial SOOF. A low G' filler placed supraperiosteally in small amounts is the key to a good result, and also avoids what is called the FOS (facial overfilled syndrome) described by Cotofana et al.<sup>55</sup>

#### Lateral SOOF

This is injected using a needle in boluses with a high G' filler supraperiosteally, or with a cannula as part of a lifting and volumizing combination. Casabona et al in 2019<sup>56</sup> demonstrated that filler injection in the lateral SOOF (i.e., lateral to the line of ligaments separating the medial from lateral face) will have a significant lifting effect, and therefore will reposition displaced tissues, making volumization easier and resulting in less volume of filler needed for volumizing



**Fig. 8.30** Midface volumization via an access point (red dot) above the zygomatic ligament into the prezygomatic space, suborbicularis oculi fat (SOOF), tear trough, and deep medial cheek fat compartment. Same access point can then be used to fill superficially bilayered approach. Usually a 25-gauge blunt flexible cannula is used.



**Fig. 8.31** Access to tear trough from the midcheek area with a 25-gauge cannula.

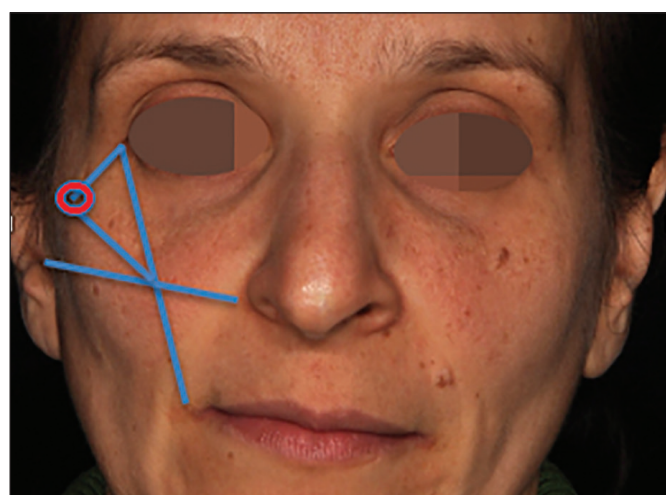the medial part. In another study Casabona et al<sup>57</sup> using a cannula showed that injecting the G point (corresponding to the lateral SOOF) alone shows a significant lift of the lower lid, inferior aspect of ala of nose, angle of mouth, and dermal location of the mandibular ligament.

So, lateral injection leads to a lift, whereas medial injection leads to volumization. Also, the lateral SOOF injection is the most efficient in terms of a lift as SVC (surface volume coefficient—volume injected to lift obtained) with 0.5 mL value being 93%, and for 1 mL to be 95%.

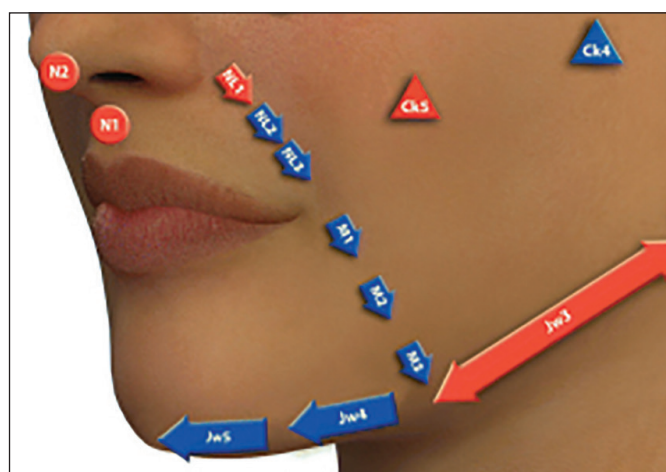


### Nasolabial Fold

This is part of the perioral area, and once the midface is done, some filler can be deposited in the upper third of the fold, deep close to the periosteum (Figs. 8.32 and 8.33). The facial vessels changing to angular vessels are close to the alar base, and avoiding intravascular injection is central to safety. Note is to be made that in post-facelift patients, the anatomy may be disturbed, and one has to be extra careful in avoiding adverse reactions. So, stay on the bone, aspirate before injecting, use small aliquots, and inject slowly, intermittently. The rest of the NLF is dynamic, affected by all the volumization which has been done before coming to the NLF, viz., the temple, zygomatic arch, and body, and the deep medial cheek compartment. De Maio<sup>49</sup> has described three points for the NLF: NL1, NL2, NL3. NL1 is at the piriform



**Fig. 8.32** “G” point described by Casabona<sup>57</sup> presenting lateral suborbicularis oculi fat (SOOF) to achieve optimum lift, so that tissues are lifted to more optimum position so that volume required in the medial face is reduced.



**Fig. 8.33** MD Codes for nasolabial folds: NL1, NL2, NL3. These are guidance points. (Adapted from de Maio 2020.<sup>49</sup>)

fossa (described earlier as the upper one-third). The remaining two are injected in the subdermal plane in very small amounts by linear threading to just efface the sharpness.

### Nose

The nose is an area which will be of special interest to plastic surgeons, as many patients are not willing to undergo surgery for minor imperfections of the nose. Also, many with low-profile noses are not sure of whether they will like the augmented look. So they get nasal augmentation done using filler as a trial, and progress to a surgical rhinoplasty later.

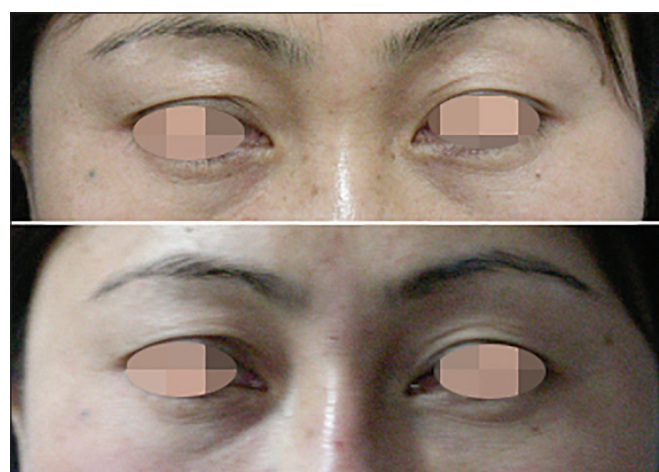#### Technique

A complete nerve block is given to the nose, like that given for a rhinoplasty under local anesthesia. The point of entry is planned in the infratip area. Using a 23- or 25-gauge, 50-mm cannula, the dorsum, supratip, nasolabial angle, and the columella can be augmented. In cases who have premaxillary hypoplasia, subalar injection and injection lateral to the alar base are also done, which helps in narrowing of the nostrils to a certain extent (Figs. 8.34 and 8.35). A secondary benefit arising from augmentation of the low-profile dorsum in an oriental-featured person is that it reduces/eliminates epicanthal folds (Fig. 8.36).

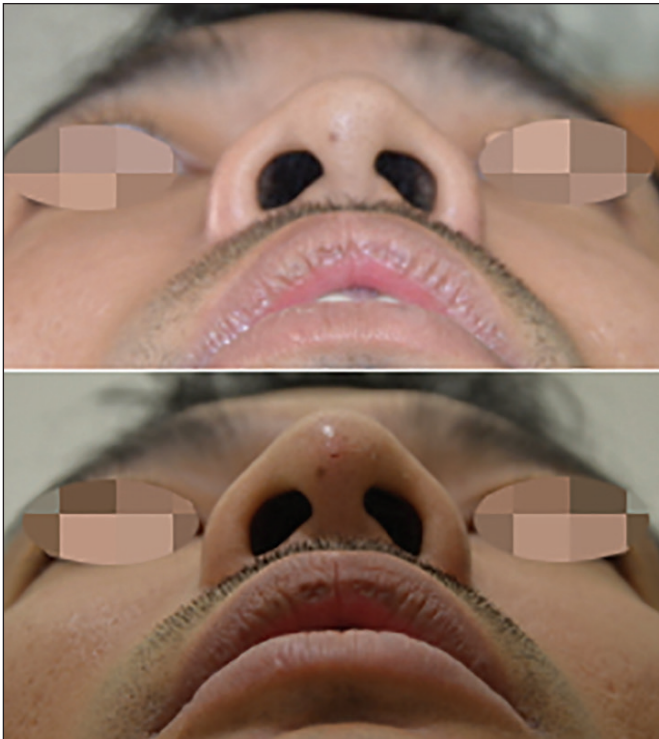
A needle is preferred over a cannula by many injectors for nasal augmentation, using a direct approach in the midline. The preperiosteal plane is injected proximally and the distal half preperichondrially.<sup>58,59</sup> Post-rhinoplasty minor aberrations like mild residual deviation of the dorsum or a depression can be corrected easily using a filler. Caution has to be observed to avoid vascular complications in this area.<sup>59</sup>

### Lower Face

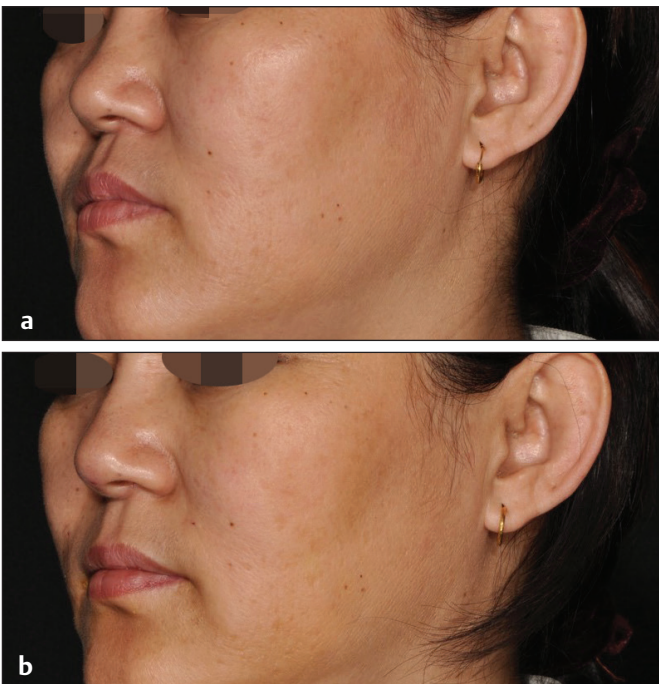
Lower face is a very interesting area for rejuvenation as it is very important for the pleasant appearance of the face. A well-contoured jawline is desirable in men and women,



**Fig. 8.34** Raising the bridge in oriental noses has the additional benefit of effacing in the epicanthal folds.



**Fig. 8.35** Nasal tip can be reshaped to make it sharper and more projecting.



**Fig. 8.36** Nonsurgical rhinoplasty in an oriental nose elevating the whole dorsum from the radix to the tip, also correcting the maxillary retrusion and improving the profile (inclination and length) of the upper lip to enable a comfortable lip closure at rest.

giving a perception of beauty and youth. It is also key to sexual dimorphism, defining male and female characteristics. The nonsurgical rejuvenation and beautification of the lower third of the face is becoming more frequent. Injectable fillers can reshape the jawline, lift soft tissues, and improve facial proportions, effectively improving the appearance of the area. This area is amenable to surgical rejuvenation procedures and many a times combined approach gives highly satisfactory result.

### Perioral Rejuvenation

Aging shows early on in the perioral region. This would include the lips, areas above and below, smokers' lines (bar code), marionette lines, and chin. The aging lips show progressive loss of volume and structure. They lose definition as the philtral columns and cupid's bow fade, the upper lip becoming thin and elongated and convex, while the lower lip becomes thin and inverted.<sup>60</sup> The elongated upper lip falls over the lip angles and becomes continuous with the marionette line worsening its appearance (**Fig. 8.37**). Better results are achieved by combining fillers with neuromodulators. It is always advisable to have a conservative approach by using lesser product. Permanent fillers should be avoided in the lips, and BontA dose used in the lips should be very small as the perioral muscles are very small and there is atrophy with age.

### Technique

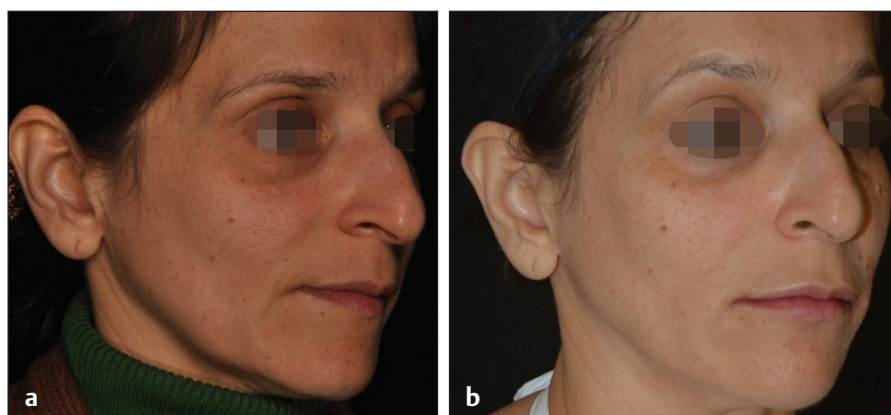When treating lips with filler we have to restore definition, add volume to lip bulk, correct asymmetry, lift lip angles, and support the lower lip at the commissures by filling the marionette triangle (**Fig. 8.38**).

Fillers offer good support to the hollow under the angles of mouth which was causing them to downturn, and injection of supporting bars of filler right along the marionette line to the prejowl sulcus will support the angle of mouth even better (**Fig. 8.37**). One should always assess dental alignment and labial/buccal support before planning filler in this area.

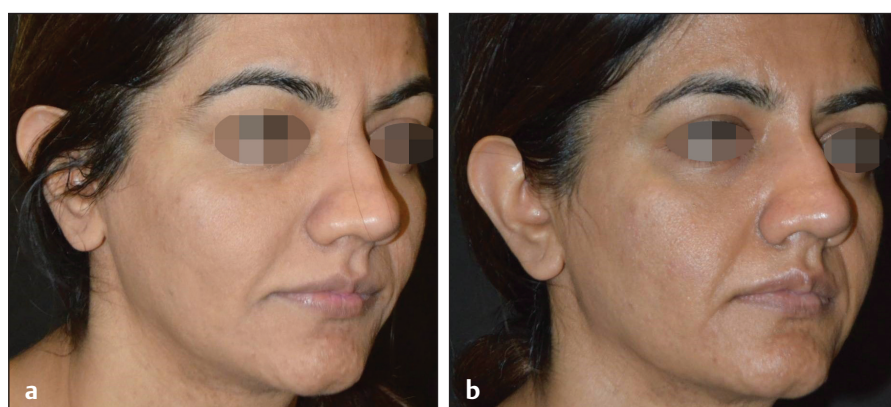The lips can be enhanced by defining the white rolls with subdermal filler placement, augmenting the flattened philtral ridges, and restoring volume to the vermillion if needed (**Fig. 8.38a, b**). Medium-to-thin viscosity fillers serve our purpose. The injections are mostly made by needle, and not by cannula. It is good to keep filler in separate compartments in the lip. Safe injection area is the dry part of vermillion and in the subcutaneous plane.

For smokers' lines, BontA injections as mentioned in the segment on toxin, and streaks of filler in the smokers' lines give a good result (**Fig. 8.17**). Perioral rejuvenation with fillers is combined usually with neuromodulators for the DAO and the mentalis, as these two muscles, if hyperactive, pull the angles of mouth down and the lower lip down, respectively. Always try to slightly under correct, review at 2 weeks and add any more filler if that is needed.





**Fig. 8.37** Perioral rejuvenation with hyaluronic acid (HA) fillers. HA fillers were injected in the nasolabial fold, marionette lines, marionette triangle, lips, mental crease, and chin.



**Fig. 8.38** (a) A 45-year-old lady with loss of lip volume and definition of lip margin. (b) One mL hyaluronic acid (HA) filler was used to improve the angle of the lips, white roll, philtral creases, and lip volume.

### Marionette Folds/Lines

These lines are responsible for droopy lips and the sad and aging look. Initially, aging starts as the marionette line appears, and with progressive underlying soft tissue loss, it develops into the marionette triangle. Then, aided by a hyperactive DAO, the fold extends vertically downward from the commissure to the prejowl sulcus at the site of the mandibular ligament.

#### Technique

In an aging face, it is prudent to start by lifting and repositioning the midface before treating the perioral region. Having dealt with the midface, using a needle we can start by placing an HA filler of medium viscosity under the oral commissure in a triangle medial to the marionette line to support the lateral lower lip from below (M1) (**Fig. 8.39**). In case the marionette triangle is wider, then we can use a 25-gauge cannula to evenly fill and support it. The remainder of the fold has to be filled for two reasons: one is to construct a continuous pillar of filler to support the commissure, and second to efface the marionette fold, injecting in the subdermal plane. The lowest point (M3) coincides with the prejowl sulcus where the injection is done at the preperiosteal level. In younger people a hyperactive DAO is usually the reason, but associated poor dental canine and premolar support may need fillers in addition to the toxin (**Fig. 8.40**).

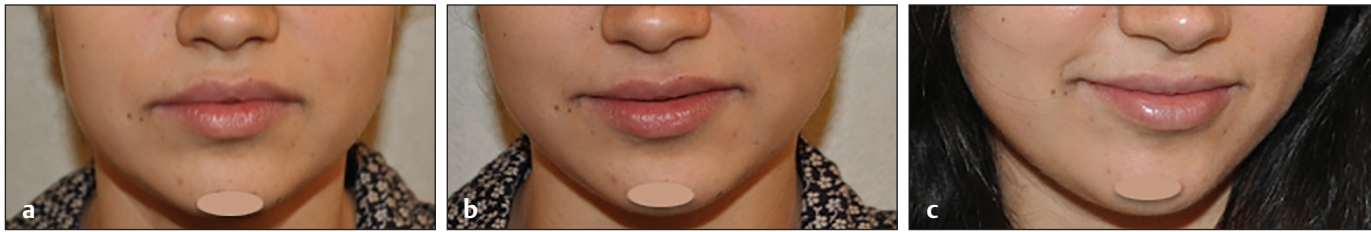### Chin

This is one of the least understood features of the face in the process of aesthetic facial improvement. A person with a well-formed and projected chin is perceived to have a strong personality, with a recessed chin implying weakness and an indecisive nature. This may be totally untrue but appearances do matter. We often notice that people with chin deficiency tend to grow beards to make themselves look aesthetically appealing. Some of the chins where implants are done can be suitably managed by filler injections, though the injections will have to be repeated every year. However, mandibular dimorphism with coexistent malocclusion (Class II) needs to be ruled out because that should be treated surgically.<sup>61</sup> The aging chin loses underlying soft and bony tissue, with the overlying skin becoming lax and irregular, and coupled with a hyperactive mentalis, the chin rides upward.

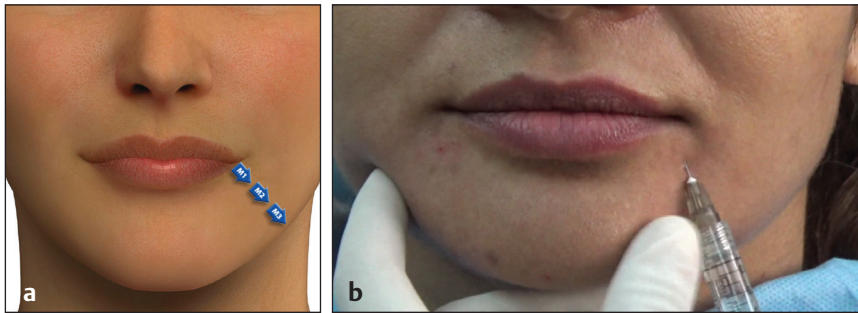
#### Technique

We place HA fillers with high viscosity and high G' supra-periosteally to add anterior projection and elongation of the chin. This can be done precisely with a needle though many clinicians prefer to combine it with a cannula. In women, the effort is to keep the chin narrow, whereas in men it is kept more square. Additional filler may be required in the superficial planes also, as the deep fat compartment is small and cannot accommodate much filler. Often if there

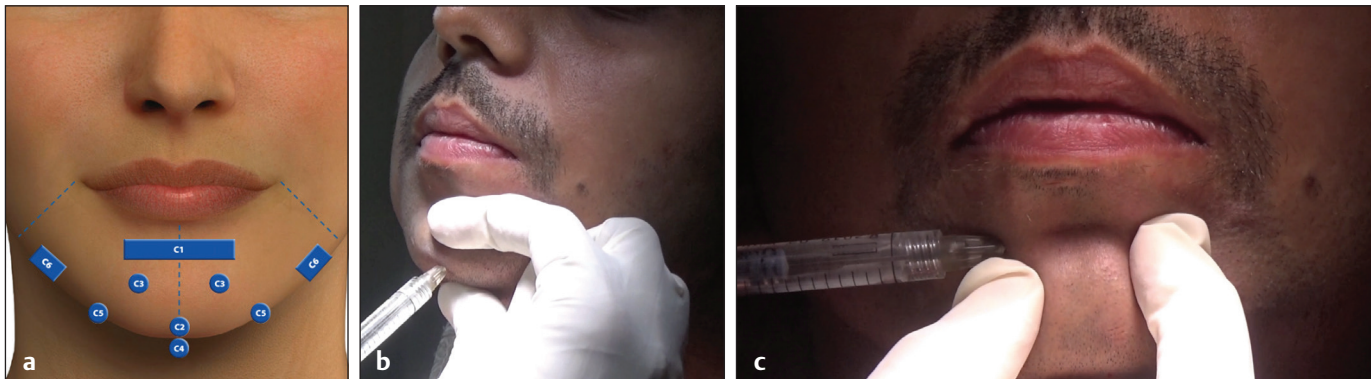




**Fig. 8.39** (a) A 26-year-old lady with a sad expression due to downturned angles because of a hyperactive depressor anguli oris (DAO) and poor support behind the angles of mouth. (b) After Botulinum toxin in the DAO. (c) Two weeks later filler under the commissures and the M1, M2, and M3 points of MD Codes were needed because of poor soft tissue support.



**Fig. 8.40** (a) MD Codes for marionette lines.<sup>49</sup> (b) Injecting under the commissure (M1) with needle.



**Fig. 8.41** (a) Chin MD Codes.<sup>49</sup> (b) Injecting the deep fat compartment of the chin at C2. (c) Injecting the labiomandibular groove: C1. Caution: Injecting too deep may end up piercing the lip mucosa.

is a coexisting hyperactive mentalis, Botulinum toxin A is injected in the midline, with 2 to 4 U helping to relax the chin. It also prevents migration of filler, as well as increases longevity of filler. Filler alone also creates a mechanical block to the hyperactivity of the mentalis muscle and thereby smoothens the chin. MD Codes for the chin as described by de Maio<sup>49</sup> gives one a good guide to assessing, injecting, and documenting chin filler injection (**Fig. 8.41**).

### Jawline

The lower face is very significant as far as perception of aging is concerned. Many women seek aesthetic medical intervention when they notice appearance of jowls and a sagging jawline. The reasons for an aging jawline are multiple, ranging from skin laxity, relative decrease in fat compartments, and absorption of bone on the mandible, resulting in a jowl, prejowl sulcus, and a poorly defined jawline. The

jawline should be straight and smooth from the chin to the gonial angle. The gonial angle measured by Upadhyay et al in 2012<sup>62</sup> was 129 degrees with no difference in men and women, and horizontally lies at the level of the oral commissure. The jawline is more horizontal in men, with the angle prominent and everted.

### Technique

To improve the jawline we need a more comprehensive approach than just treating the jawline itself. For best results we need to address the middle face first, followed by the lower face. We treat from superiorly to inferiorly. The filler (HA fillers commonly) can be injected either by needle, or a combination of needle and cannulas. Once the midface filler injections help reposition the tissues by lifting them, the jawline can be defined and enhanced from the chin to the angle of mandible.

Given below are the points and the sequence of injecting to get optimal results.<sup>49</sup> Also mentioned is the depth (plane) of injection, with approximately 0.05 to 0.1 mL per injection in case of a needle being used (**Figs. 8.42 and 8.43**):

- . Lateral cheek lift by injecting at the zygomatic arch—supraperiosteal.
- . Lateral cheek lift by injecting at the zygomatic eminence—supraperiosteal.
- . Anterior projection of the cheek, (i.e., the medial malar area)—supraperiosteal.
- . Upper preauricular region—subcutaneous.
- . Lower preauricular region inferior to the tragus—subcutaneous.
- . Mandibular angle—supraperiosteal.<sup>63</sup>
- . Postjowl sulcus—supraperiosteal and subcutaneous both.
- . Prejowl sulcus—supraperiosteal and subcutaneous both.
- . Marionette triangle—subcutaneous.
- . Chin—supraperiosteal and subcutaneous both.

For a subcutaneous injection on the jaw line into the superficial fat compartment, it is advisable to pinch the skin to avoid the facial vessels at the anteroinferior angle of the masseter.<sup>63</sup> It is important not to inject into the jowl bulge as it will exaggerate it. The jowl is the no go zone while improving the definition of the jawline.

### Adverse Effects of Fillers

Soft tissue augmentation is among the most popular aesthetic procedures in the world today. With proper training of anatomy, injection technique, and asepsis, results

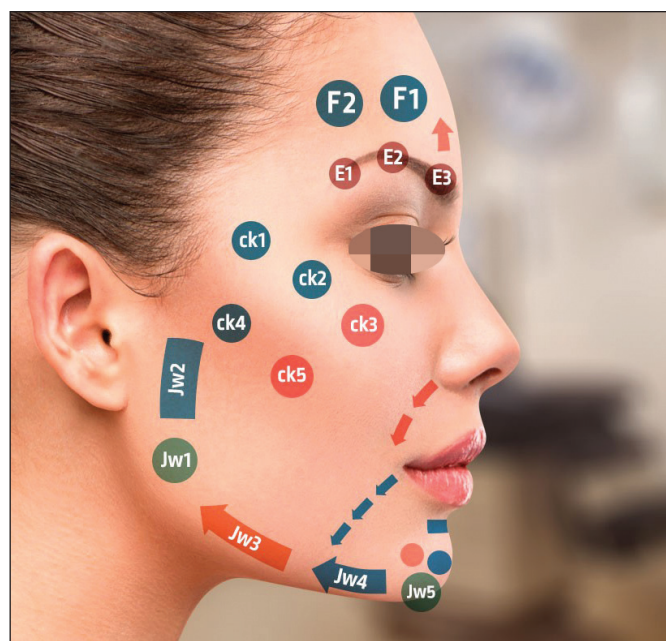
are pleasing and well tolerated. Still, in the best of hands, complications can occur. An in-depth knowledge of side effects is essential for early detection and treatment of these complications.

Though generally safe, complications can occur with temporary fillers. Compared to temporary fillers, permanent filler complications are difficult to treat since the product does not dissipate and remains in the body. The products available for augmentation can be divided into biodegradable, semibiodegradable, and nonbiodegradable. This classification correlates with the longevity of the results—as being temporary (results last 6–12 mo), semipermanent (duration up to 18 mo), or permanent (up to a lifetime). The complications may be injector related, patient related, or product related.

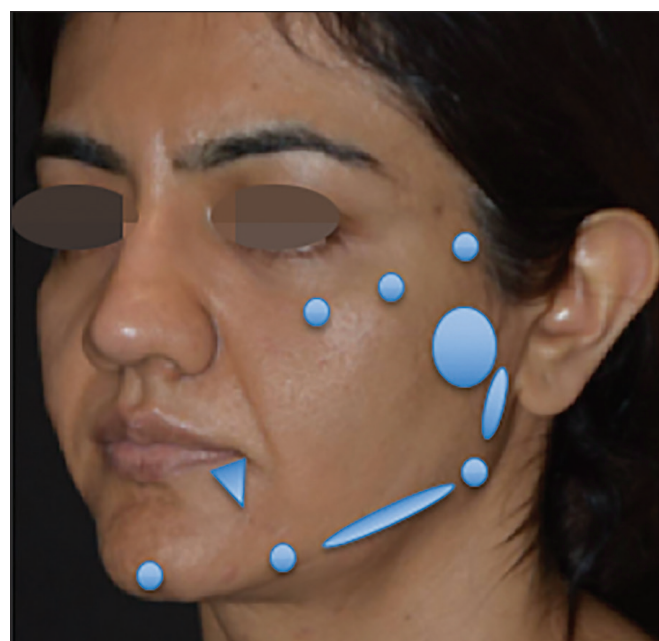
The most frequent, early onset complications with fillers are related to the injection site, such as pain, erythema, edema, ecchymosis, and bruising. These mostly resolve in 4 to 7 days and patient should be made aware prior to the procedure. Other complications are inappropriately placed filler,<sup>64</sup> vascular occlusion, hypersensitivity, malar edema, and paresthesias. Delayed onset complications include delayed onset edema, inflammatory and noninflammatory nodules, biofilms, and delayed hypersensitivity.

### Pain

This is due to hydrostatic separation of the tissue during the injection as well as due to multiple needle punctures. Pain can be minimized by topical anesthetic creams, icing, distraction techniques, and inclusion of lidocaine in the filler material which now comes in prepackaged syringes.



**Fig. 8.42** Jawline rejuvenation schema. (Adapted from de Maio 2020<sup>49</sup>.)



**Fig. 8.43** Comprehensive 10-point jawline rejuvenation will get optimal results.

### Edema and Bruising

HA fillers are known to cause injection site–related edema and bruising. Bruising is due to extravasation of blood due to puncturing a vein inadvertently, or due to preexistent coagulopathies. Chances of bruising can be minimized by avoiding highly vascular areas, using smaller gauge needles (27–31 gauge), slower injections, injecting smaller volumes in one prick, minimizing the number of pricks, or using blunt cannulas.

It is advisable to discontinue blood thinning medications in case it is safe to do so about 7 days prior to injection. To reduce bruising during the procedure it is advisable to apply firm pressure on the site of bleeding, apply cold compresses, and topical vitamin K cream postprocedure.<sup>65</sup>

### Erythema

It is caused by hyperemia of superficial capillaries, can also occur postmassage, and is usually temporary. Mostly nothing is needed for erythema, but if it persists then antihistamines, medium potency topical steroid, and Vitamin K creams can be prescribed. If redness persists for several days it may be indicative of hypersensitivity.

### Infections

As with any procedure that breaches the skin, acute skin infections can occur after fillers injections and could be bacterial, fungal, or viral. Acute infections can be minimized by more stringent aseptic cleaning techniques utilizing alcohol or chlorhexidine. Acute bacterial infections which are most likely seen are due to staphylococcus and streptococcus, and may present as single or multiple tender erythematous and/or fluctuant nodules. These may be accompanied by fever and fatigue. Infections should not be confused with hypersensitivity reactions which is accompanied by itching and absence of fever.<sup>66</sup>

Early onset skin infections should be treated immediately with oral antibiotics against *Staphylococcus aureus*. In more serious cases IV antibiotics should be administered. When a lesion that appears infectious in nature appears more than 2 weeks after the filler injection, it may be suggestive of an atypical mycobacterial infection. An infection may rarely manifest as an abscess from one week to several years after the treatment.

Rarely (in <1.5%), there may be reactivation of herpes that may occur 24 to 48 hours postinjection. Postfiller if herpes is activated, it should be treated with antiviral therapy and appropriate antibiotics.

### Nodules and Lumps

Sometimes inadequate assessment, improper injection technique, and incorrect placement of product may result in placement of too much volume in a small area, resulting in visible lumps. These are very evident in the periorbital and

perioral areas. Persistent nodules and lumps are normally resistant to the normal HA degradation process and may not resolve spontaneously. They can be reversed by hyaluronidase injections intralesionally.<sup>67</sup>

### Tyndall Effect

In the tear-trough region, a bluish discoloration is observed over the injected area. This is due to injecting excessive product of a high  $G'$  in too superficial a plane. This is due to a Tyndall effect, (i.e., scattering of light by particles in a suspension). High-frequency blue light is scattered more easily than red light by a thick layer of a high concentration filler placed superficially and becomes the predominantly visible light.

### Hypersensitivity Reactions

Though rare, the reaction can manifest as acute, excessive, persistent swelling following filler injection. The reaction can last for >6 weeks. Fillers are essentially foreign bodies and some people may develop a hypersensitivity to the product as a result of IgE-mediated immune response (type 1 hypersensitivity reaction or a delayed type IV hypersensitivity).

### Malar Edema

This can develop, or existing malar edema can get exaggerated, while injecting the tear troughs and periorbital hollowing in patients prone to preexisting malar edema (those with malar bags). This happens because the fillers further compromise the already compromised lymphatic circulation.<sup>68</sup>

### Vascular Compromise

It is a rare but critical complication and should be managed as an emergency. An in-depth knowledge of facial anatomy is crucial to avoiding vascular complications. Vascular occlusion can result in tissue necrosis and disfigurement and in rare cases in blindness. Tissue necrosis manifests as blanching and severe pain followed later by violaceous discoloration.<sup>69</sup> Vascular compromise is mostly due to intravascular arterial occlusion and can also occur due to external compression of vessels by the filler. The area prone to maximum risk is the glabella due to inadvertent injection into the supratrochlear artery (an end artery) and its branches. Other vessels at risk are the angular artery at the medial canthus of the eye and the lateral nasal artery and their branches.

To limit the damage and reverse the occlusion one should perfuse the area with hyaluronidase,<sup>70</sup> massage, apply warm compresses and nitroglycerin paste, and give aspirin tablets. To prevent vascular complications, one should aspirate every time before injecting, inject slowly, small amount (<0.1 mL) in one place and also keep the needle tip moving while injecting. Though complication rates with temporary fillers are low, it is important to identify and manage them.



## Full-Face Rejuvenation

Patients many times come with specific issues related to some areas of the face, like the glabellar frown lines, or tear troughs, or NLFs, or just the jowls.<sup>71</sup> But sometimes, they come with global issues like looking older, tired, or just not looking good. Other times, they may come with emotional issues like “I look angry, or sad, or tired.” The tendency to only treat specific issues does not always bring about a happy patient or a favorable outcome.<sup>72</sup> This happens because the features of aging are global, and we did not assess/appreciate the overall shape, proportions, symmetry, or sexual dimorphism in the face.

### Assessment

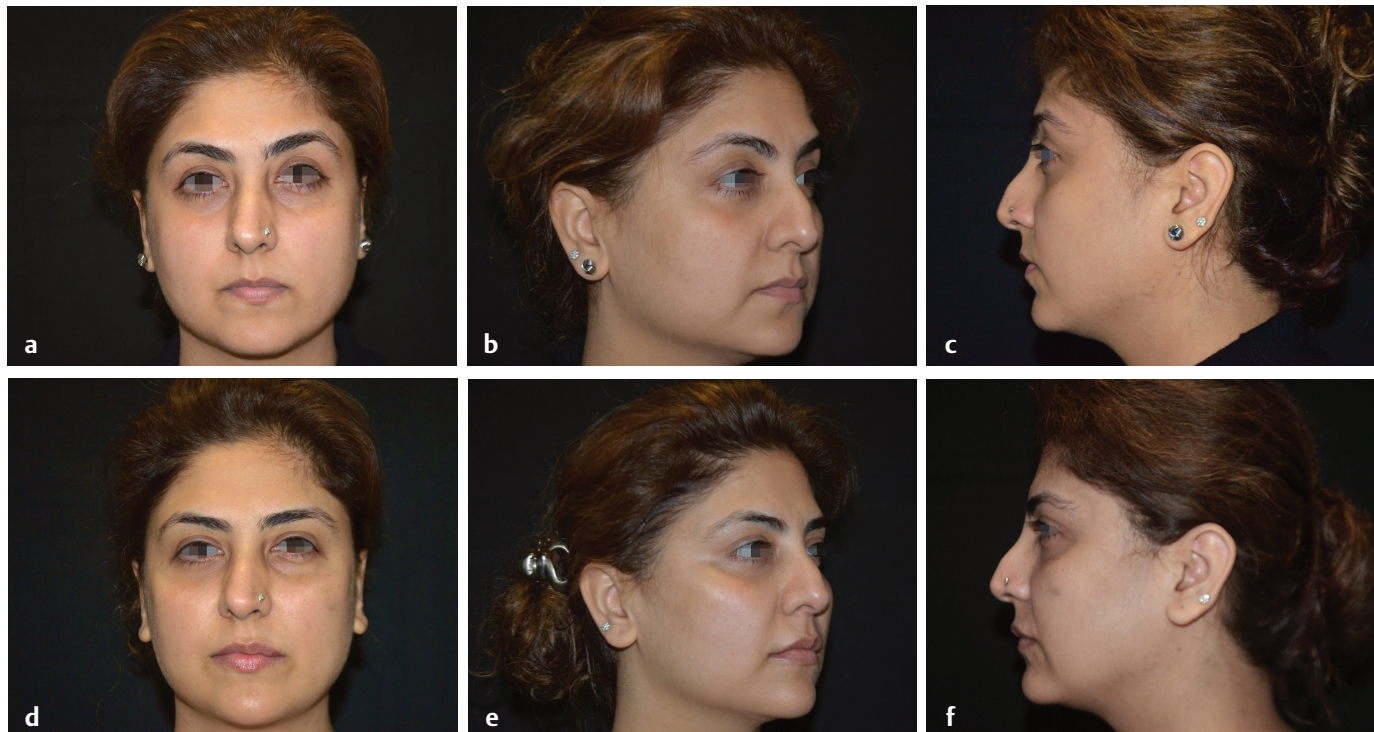A detailed full-face assessment should be done, which takes into account, the shape of the face, the proportions (or averageness) of different thirds of the face, symmetry, features of sexual dimorphism. Faces age differently depending on their structural framework; faces with prominent structural features like high cheekbones offer less of sag and more of deflation or volume deficiency. Contrast this with those with poor structural support to the midface, having heavy chubby

faces and small lower third of faces, causing mostly descent with tissue excess in the midface making lower third deficiency even more prominent.

### Planning and Execution

Note should be made as to what features are contributing to deterioration of that face, and also how that face is going to age in future. This will finally decide the general direction of our global rejuvenation plan as suggested earlier. We always start treating from the top—temples, forehead, brows—to midface lifting and volumizing, and go onto lower third which is primarily correcting proportion and restoring features (**Fig. 8.44**). Then individual features are restored and enhanced, if not already dealt with.

Faces with mild-to-moderate issues can be dealt best by combination treatments consisting not only of injectables but preceded many times by energy-based treatments which lay the groundwork for a tighter skin envelope to optimize nonsurgical treatment. A definite line should be drawn as to whether a surgical option would achieve a better outcome, entirely on its own, or with adjunctive injectable treatment in most of the cases. Unpleasant and unfavorable outcomes usually arise from trying to solve all problems with only one modality—nonsurgical or surgical.



**Fig. 8.44** (a) Frontal view: pretreatment. (b) Right oblique view: pretreatment. (c) Left profile view pretreatment. (d) Frontal view: post treatment—note improved chin height and proportion of lower  $\frac{1}{3}$ rd of the face to middle and upper  $\frac{1}{3}$ rd and raised lid cheek junction. (e) Right oblique view: post treatment—better positioned cheek eminence, lip profile, and chin contour. (f) Left profile view: post treatment—note increased chin height and improved lip profile.

## Conclusion

A combination of neurotoxins and filler injections is the Gold Standard for treating the aging face by nonsurgical means. Neurotoxins work to reduce or ameliorate rhytides as well as alter facial expressions. To deliver optimal results we need to understand the functional interplay between the facial muscles. Temporary fillers are preferred to the permanent fillers. The cornerstone of a good treatment is a proper facial assessment. Satisfactory results cannot be achieved if the clinician underassesses the face or does not understand what the patient wants. Therefore, it is wise to plan a full-face treatment with fillers over multiple sessions. It is important to understand that we should inject the right product, in the right plane, in the right amount, and in the right patient. A good understanding of the facial anatomy is important to perform safe and effective treatment.

## References

1. Wu W. Non-surgical facial rejuvenation with the 4R principle: innovative uses of BOTOX and facelifting with the Woffles Lift, a barbed suture sling. In: *Aesthetic surgery of the facial mosaic*. Berlin, Heidelberg: Springer; 2006
2. Jacono AA, Malone MH, Lavin TJ. Nonsurgical facial rejuvenation procedures in patients under 50 prior to undergoing facelift: habits, costs, and results. *Aesthet Surg J* 2017;37(4):448–453
3. Wollina U, Goldman A. Minimally invasive aesthetic procedures in young adults. *Clin Cosmet Investig Dermatol* 2011;4:19–26
4. Kapoor KM, Chatrath V, Anand C, et al. On behalf of the Indian Facial Aesthetics Expert Group Consensus Recommendations for Treatment Strategies in Indians Using Botulinum Toxin and Hyaluronic Acid Fillers. Consensus recommendations for treatment strategies in Indians using botulinum toxin and hyaluronic acid fillers. *Plast Reconstr Surg Glob Open* 2017; 5(12):e1574
5. Carruthers JA, Lowe NJ, Menter MA, et al; BOTOX Glabellar Lines I Study Group. A multicenter, double-blind, randomized, placebo-controlled study of the efficacy and safety of botulinum toxin type A in the treatment of glabellar lines. *J Am Acad Dermatol* 2002;46(6):840–849
6. Beer KR, Boyd C, Patel RK, Bowen B, James SP, Brin MF. Rapid onset of response and patient-reported outcomes after onabotulinum toxin A treatment of moderate-to-severe glabellar lines. *J Drugs Dermatol* 2011;10(1):39–44
7. Carruthers A, Carruthers J, Lowe NJ, et al. For the BOTOX® Glabellar Lines I & II Study Groups. One-year, randomised, multicenter, two-period study of the safety and efficacy of repeated treatments with botulinum toxin type A in patients with glabellar lines. *J Clin Res* 2004;7:1–20
8. Beer KR, Shamban AT, Avelar RL, Gross JE, Jonker A. Efficacy and safety of prabotulinum toxin A for the treatment of glabellar lines in adult subjects: results from 2 identical phase III studies. *Dermatol Surg* 2019;45(11):1381–1393
9. Carruthers J, Solish N, Humphrey S, et al. Injectable daxibotulinum toxin A for the treatment of glabellar lines: a phase 2, randomized, dose-ranging, double-blind, multicenter comparison with onabotulinum toxin A and placebo. *Dermatol Surg* 2017;43(11):1321–1331
10. Sloop RR, Cole BA, Escutin RO. Reconstituted botulinum toxin type A does not lose potency in humans if it is refrozen or refrigerated for 2 weeks before use. *Neurology* 1997;48(1): 249–253
11. Hexsel DM, De Almeida AT, Rutowitsch M, et al. Multicenter, double-blind study of the efficacy of injections with botulinum toxin type A reconstituted up to six consecutive weeks before application. *Dermatol Surg* 2003;29(5):523–529, discussion 529
12. Hsu TS, Dover JS, Arndt KA. Effect of volume and concentration on the diffusion of botulinum exotoxin A. *Arch Dermatol* 2004;140(11):1351–1354
13. Carruthers A, Carruthers J, Cohen J. Dilution volume of botulinum toxin type A for the treatment of glabellar rhytides: does it matter? *Dermatol Surg* 2007;33(1 Spec No.):S97–S104
14. Carruthers J, Lowe NJ, Menter MA, Gibson J, Eadie N, For the Botox Glabellar Lines II Study Group. Double-blind, placebo-controlled study of the safety and efficacy of botulinum toxin type A for patients with glabellar lines. *Plast Reconstr Surg* 2003;112(5):21S–30S
15. Carruthers A, Carruthers J. Eyebrow height after botulinum toxin type A to the glabella. *Dermatol Surg* 2007;33:S26–S31
16. Horne DF, Rohrer TE. Shaping of the eyebrows with botox. In: *Hartstein ME, Holds JB, Massry GG, eds. Pearls and pitfalls in cosmetic oculoplastic surgery*. New York, NY: Springer; 2008
17. Ahn MS, Catten M, Maas CS. Temporal brow lift using botulinum toxin A. *Plast Reconstr Surg* 2000;105(3):1129–1135, discussion 1136–1139
18. Carruthers A, Carruthers J, Fagien S, Lei X, Kolodziejczyk J, Brin MF. Repeated onabotulinum toxin A treatment of glabellar lines at rest over three treatment cycles. *Dermatol Surg* 2016;42(9): 1094–1101
19. Sundaram H, Liew S, Signorini M, et al; Global Aesthetics Consensus Group. Global aesthetics consensus: hyaluronic acid fillers and botulinum toxin type A—recommendations for combined treatment and optimizing outcomes in diverse patient populations. *Plast Reconstr Surg* 2016;137(5):1410–1423
20. Carruthers JD, Faris SE. Neurotoxin injection for lower eyelid roll. In: *Kontis TC, ed. Cosmetic injection techniques: a text and video guide to neurotoxins and fillers*. Lacombe VG: Thieme Verlagsgruppe; 2013: Ch. 10, p. 32
21. Flynn TC, Carruthers JA, Carruthers JA. Botulinum-A toxin treatment of the lower eyelid improves infraorbital rhytides and widens the eye. *Dermatol Surg* 2001;27(8):703–708
22. Carruthers A, Carruthers J, Cohen J. A prospective, double-blind, randomized, parallel- group, dose-ranging study of botulinum toxin type A in female subjects with horizontal forehead rhytides. *Dermatol Surg* 2003;29(5):461–467
23. Ramey NA, Woodward JA. Mechanisms of blepharoptosis following cosmetic glabellar chemodenervation. *Plast Reconstr Surg* 2010;126(5):248e–249e
24. Wijemanne S, Vijayakumar D, Jankovic J. Apraclonidine in the treatment of ptosis. *J Neurol Sci* 2017;376:129–132
25. Mendonça TB, Lummertz AP, Bocaccio FJ, Procianny F. Effect of low-concentration, nonmydriatic selective alpha-adrenergic agonist eyedrops on upper eyelid position. *Dermatol Surg* 2017;43(2):270–274
26. Paloma V, Samper A. A complication with the aesthetic use of Botox: herniation of the orbital fat. *Plast Reconstr Surg* 2001;107(5):1315
27. Goldman MP. Festoon formation after infraorbital botulinum A toxin: a case report. *Dermatol Surg* 2003;29(5):560–561, discussion 561



28. Frankel AS. Botox for rejuvenation of the periorbital region. *Facial Plast Surg* 1999;15(3):255–262
29. Kane MA. Classification of crow's feet patterns among Caucasian women: the key to individualizing treatment. *Plast Reconstr Surg* 2003; 112(5, Suppl):33S–39S
30. Benedetto A. Cosmetic uses of botulinum toxin A in the midface. In: Benedetto A, ed. *Botulinum toxins in clinical aesthetic practice*. Essex, UK: Informa Healthcare; 2011:104–139
31. Dayan SH, Kempiners JJ. Treatment of the lower third of the nose and dynamic nasal tip ptosis with Botox. *Plast Reconstr Surg* 2005;115(6):1784–1785
32. Bilal R. The gum and tooth show preference during smile by the patients visiting Qassim university dental hospital. *Int J Applied Dent Sci* 2016;2(1):24–27
33. Mazzuco R, Hexsel D. Gummy smile and botulinum toxin: a new approach based on the gingival exposure area. *J Am Acad Dermatol* 2010;63(6):1042–1051
34. Hwang WS, Hur MS, Hu KS, et al. Surface anatomy of the lip elevator muscles for the treatment of gummy smile using botulinum toxin. *Angle Orthod* 2009;79(1):70–77
35. Polo M. Botulinum toxin type A in the treatment of excessive gingival display. *Am J Orthod Dentofacial Orthop* 2005;127(2):214–218, quiz 261
36. Carruthers J, Fagien S, Matarasso SL; Botox Consensus Group. Consensus recommendations on the use of botulinum toxin type a in facial aesthetics. *Plast Reconstr Surg* 2004; 114(6, Suppl):1S–22S
37. Benedetto AV. Cosmetic uses of botulinum toxin A in the lower face and upper chest. In: *Botulinum toxin in clinical dermatology*. UK: CRC Press, Informa Group; 2006: Ch 5, pp. 205–206
38. Simoni RD, Hill RL, Vaughan M, et al. JBC Centennial. The discovery of hyaluronan by Karl Meyer. *J Biol Chem* 2002;277:61–62
39. Coleman SR. Injectable silicone returns to the United States. *Aesthet Surg J* 2001;21(6):576–578
40. Mest DR, Humble G. Safety and efficacy of poly-L-lactic acid injections in persons with HIV-associated lipoatrophy: the US experience. *Dermatol Surg* 2006;32(11):1336–1345
41. Summary of safety and effectiveness data. [https://www.accessdata.fda.gov/cdrh\\_docs/pdf5/P050052B.pdf](https://www.accessdata.fda.gov/cdrh_docs/pdf5/P050052B.pdf). Accessed August 20, 2020
42. Eça LP, Pinto DG, de Pinho AM, Mazzetti MP, Odo ME. Autologous fibroblast culture in the repair of aging skin. *Dermatol Surg* 2012;38(2):180–184
43. Rohrich RJ, Pessa JE. The fat compartments of the face: anatomy and clinical implications for cosmetic surgery. *Plast Reconstr Surg* 2007;119(7):2219–2227, discussion 2228–2231
44. Vedamurthy M. Beware what you inject: complications of injectables—dermal fillers. *J Cutan Aesthet Surg* 2018;11(2):60–66. <http://www.jcasonline.com/text.asp?2018/11/2/60/240031>. Accessed August 9, 2020
45. de Maio M. Myomodulation with injectable fillers: an innovative approach to addressing facial muscle movement. *Aesthetic Plast Surg* 2018;42(3):798–814
46. Rho NK, Chang YY, Chao YY, et al. Consensus recommendations for optimal augmentation of the Asian face with hyaluronic acid and calcium hydroxylapatite fillers. *Plast Reconstr Surg* 2015;136(5):940–956
47. Kim J. Novel forehead augmentation strategy: forehead depression categorization and calcium-hydroxyapatite filler delivery after tumescent injection. *Plast Reconstr Surg Glob Open* 2018;6(9):e1858
48. Sundaram H, Carruthers J. The glabella and central brow. In: Carruthers J, Carruthers A, eds. *Procedures in cosmetic dermatol: soft tissue augmentation*. 3rd ed. London: Elsevier Saunders; 2013:88–99
49. de Maio M. MD Codes™: a methodological approach to facial aesthetic treatment with injectable hyaluronic acid fillers. *Aesthetic Plast Surg* 2020. <https://doi.org/10.1007/s00266-020-01762-7>
50. Rzany B, DeLorenzi C. Understanding, avoiding, and managing severe filler complications. *Plast Reconstr Surg* 2015; 136(5, Suppl):196S–203S
51. Papageorgiu K, Mancini R, Garneau HC, Chang S-H, Jarullazada I, King A. A Three-Dimensional Construct of the Aging Eyebrow: The Illusion of Volume Loss. *Aesth Surg J* 2012;32(1):46–57
52. Papageorgiou KI, Mancini R, Garneau HC, et al. A three-dimensional construct of the aging eyebrow: the illusion of volume loss. *Aesthet Surg J* 2012;32(1):46–57
53. Pessa JE. An algorithm of facial aging: verification of Lambros's theory by three-dimensional stereolithography, with reference to the pathogenesis of midfacial aging, scleral show, and the lateral suborbital trough deformity. *Plast Reconstr Surg* 2000;106(2):479–488, discussion 489–490
54. De Maio M. Treatment planning. In: de Maio M, Rzany B, eds. *Chapter 4: Injectable fillers in aesthetic medicine*. Berlin, Heidelberg: Springer Link Verlag; 2014:52–55
55. Cotofana S, Gotkin RH, Frank K, Lachman N, Schenck TL. Anatomy behind the facial overfilled syndrome: the transverse facial septum. *Dermatol Surg* 2020;46(8):e16–e22
56. Casabona G, Frank K, Koban KC, et al. Lifting vs volumizing: the difference in facial minimally invasive procedures when respecting the line of ligaments. *J Cosmet Dermatol* 2019;10.1111/jocd.13089 (Online ahead of print)
57. Casabona G, Bernardini FP, Skippen B, et al. How to best utilize the line of ligaments and the surface volume coefficient in facial soft tissue filler injections. *J Cosmet Dermatol* 2020;19(2):303–311
58. Harb A, Brewster CT. The nonsurgical rhinoplasty: a retrospective review of 5000 treatments. *Plast Reconstr Surg* 2020; 145(3):661–667
59. Scheuer JF III, Sieber DA, Pezeshk RA, Campbell CF, Gassman AA, Rohrich RJ. Anatomy of the facial danger zones: maximizing safety during soft-tissue filler injections. *Plast Reconstr Surg* 2017;139(1):50e–58e
60. Lévêque JL, Goubanova E. Influence of age on the lips and perioral skin. *Dermatology* 2004;208(4):307–313
61. Arroyo HH, Olivetti IP, Lima LF, Jurado JR. Clinical evaluation for chin augmentation: literature review and algorithm proposal. *Rev Bras Otorrinolaringol (Engl Ed)* 2016;82(5):596–601
62. Upadhyay RB, Upadhyay J, Agrawal P, Rao NN. Analysis of gonial angle in relation to age, gender, and dentition status by radiological and anthropometric methods. *J Forensic Dent Sci* 2012;4(1):29–33
63. de Maio M, Wu WTL, Goodman GJ, Monnheit G. Facial assessment and injection guide for Botulinum toxin and injectable hyaluronic acid fillers: focus on the lower face. *Plast Reconstr J* 2017;140(3):393e–404e
64. Cohen JL. Understanding, avoiding, and managing dermal filler complications. *Dermatol Surg* 2008;34(Suppl 1):S92–S99
65. King M. The management of bruising following nonsurgical cosmetic treatment. *J Clin Aesthet Dermatol* 2017;10(2):E1–E4



66. Funt D, Pavicic T. Dermal fillers in aesthetics: an overview of adverse events and treatment approaches. *Clin Cosmet Investig Dermatol* 2013;6:295–316
67. Daines SM, Williams EF. Complications associated with injectable soft-tissue fillers: a 5-year retrospective review. *JAMA Facial Plast Surg* 2013;15(3):226–231
68. Funt DK. Avoiding malar edema during midface/cheek augmentation with dermal fillers. *J Clin Aesthet Dermatol* 2011;4(12):32–36
69. Beleznyay K, Humphrey S, Carruthers JD, Carruthers A. Vascular compromise from soft tissue augmentation: experience with 12 cases and recommendations for optimal outcomes. *J Clin Aesthet Dermatol* 2014;7(9):37–43
70. DeLorenzi C. New high dose pulsed hyaluronidase protocol for hyaluronic acid filler vascular adverse events. *Aesthet Surg J* 2017;37(7):814–825
71. Sobanko JF, Taglienti AJ, Wilson AJ, et al. Motivations for seeking minimally invasive cosmetic procedures in an academic outpatient setting. *Aesthet Surg J* 2015;35(8):1014–1020
72. Michaud T, Gassia V, Belhaouari L. Facial dynamics and emotional expressions in facial aging treatments. *J Cosmet Dermatol* 2015;14(1):9–21